



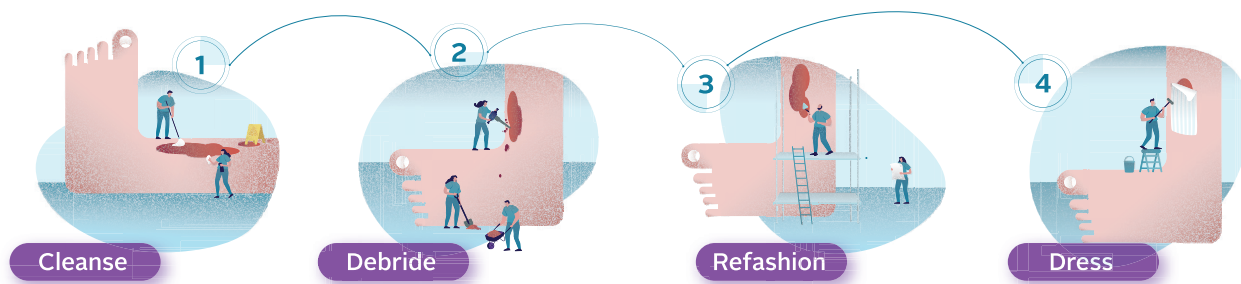
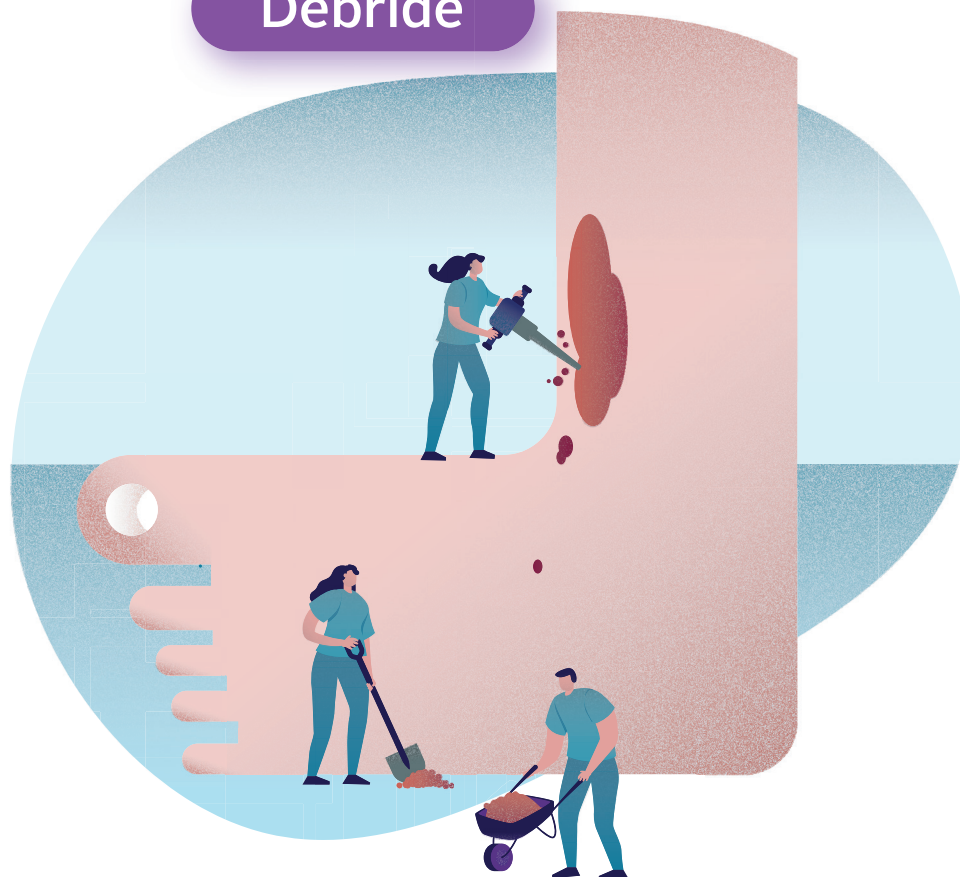ChloraSolv®



RLS GLOBAL
Gentle Methods

Introducing ChloraSolv®: an innovative technology for debridement and wound bed preparation

Debride



 **convatec**
— forever caring —

JW C
journal of wound care



Wound Hygiene



MA Healthcare

Project editor: Benjamin Wakefield

Project manager: Angela Shaw

Associate publisher: Tracy Cowan

Design: Fonthill Creative

Managing director: Anthony Kerr

anthony.kerr@markallengroup.com

Published by MA Healthcare Ltd

St Jude's Church, Dulwich Road, London, SE24 0PB, UK

+44 (0)20 7738 6726

www.markallengroup.com

Supported and produced by Mark Allen Medical Communications

www.mamedcomms.com

© MA Healthcare Ltd 2022

Supported by ConvaTec Ltd

ChloraSolv is a trademark of RLS Global AB and distributed for use by ConvaTec. ConvaTec, the ConvaTec logo, the Wound Hygiene logo and the cover artwork are trademarks or registered trademarks or copyrighted materials of ConvaTec Inc. Any use without the express written consent of ConvaTec Inc is forbidden.

All rights reserved. No reproduction, transmission or copying of this publication is allowed without written permission. No part of this publication may be reproduced, stored in a retrieval system, or transmitted in any form or by any means, mechanical, electronic, photocopying, recording, or otherwise, without the prior written permission of MA Healthcare or in accordance with the relevant copyright legislation.

Declarations of interest

All authors are independent health professionals who received a fee for their contributions. Leanne Atkin has received honoraria from ConvaTec to provide education sessions and attend expert panel meetings. Joy Tickle has received consultancy fees from ConvaTec. Kimberley Wilde has no interests to declare.

Contents

4 Foreword

Leanne Atkin, Vascular Nurse Consultant, Mid Yorkshire Hospitals NHS Trust and University of Huddersfield

5 Introducing a new approach to debridement and wound bed preparation

Leanne Atkin, Vascular Nurse Consultant, Mid Yorkshire Hospitals NHS Trust and University of Huddersfield

Implementation in practice: case studies

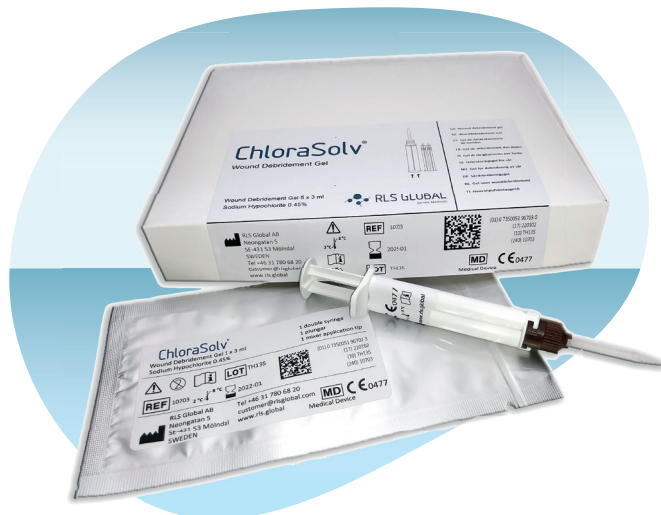13 Case studies 1–3: leg ulcers

Joy Tickle, Tissue Viability Nurse Consultant, Isle of Wight NHS Trust, UK

18 Case studies 4–6: diabetic foot ulcers

Kimberley Wilde, Advanced Podiatrist, Manchester University NHS Foundation Trust, UK

22 Conclusion



Foreword



Leanne Atkin, Vascular Nurse Consultant, Mid Yorkshire Hospitals NHS Trust and University of Huddersfield

Debridement remains a cornerstone of good wound bed preparation, where it is used to remove devitalised tissue and biofilm, as well as promote wound healing. Debridement plays a key role in all wound management protocols and frameworks, such as Wound Hygiene¹ and the TIMERS concept.²

Debridement, a distinct process from wound cleansing, involves removing adherent contaminated or dead tissue and bioburden/biofilm from the wound and its edges^{1,3} to facilitate and promote granulation tissue formation and healing. Debridement removes barriers to healing, such as debris, necrosis, slough, bacteria and biofilm; reduces the risk of infection; improves the microcirculation; normalises biochemistry, including metalloproteinase regulation; and stimulates the wound edges.³

For debridement to be effective, it needs to be implemented regularly.⁴⁻⁵ However, the wide range of debridement methods available, each with its own benefits and disadvantages, can make this challenging for health professionals, particularly as the standard-of-care option—sharp debridement—requires specialist training and is invasive, with the potential to cause pain, bleeding and tissue trauma. For many wound-

care practitioners, the only option for wound debridement is the use of dressings to encourage autolytic or mechanical debridement. Autolytic debridement is effective, but it is slow and often takes weeks to fully occur; it also poses the risk of invasive infection and periwound maceration.¹ Meanwhile, mechanical debridement is not particularly effective on hard eschar and adherent slough.⁶

Therefore, there is a need for an alternative method of debridement that is accessible to all health professionals and combines the effectiveness of sharp debridement with the ease of use of the most popular mechanical methods. This would be able to expedite healing and improve outcomes and quality of life for patients, as well as reduce the economic burden of wound care.

ChloraSolv® Wound Debridement Gel is a novel chemo-mechanical debridement treatment for leg ulcers and diabetic foot ulcers that requires minimal training and can be applied 1–2 times weekly until the slough and necrosis are removed. Evidence suggests that using ChloraSolv reduces the need for sharp debridement, resulting in reduced bacterial loads and improved wound healing.⁷ Therefore, it offers a potential paradigm shift in wound debridement.



References

1. Murphy C, Atkin L, Swanson T et al. Defying hard-to-heal wounds with an early antibiofilm intervention strategy: wound hygiene. *J Wound Care*. 2020; 29(S3b):S1–S26. <https://doi.org/10.12968/jowc.2020.29.sup3b.s1>
2. Atkin L, Bucko Z, Montero EC et al. Implementing TIMERS: the race against hard-to-heal wounds. *J Wound Care*. 2019; 28(S3a):S1–S50. <https://doi.org/10.12968/jowc.2019.28.sup3a.s1>
3. Stroh R, Dissemond J, Jordan O'Brien J et al. Debridement: an updated overview and clarification of the principle role of debridement. *J Wound Care*. 2013; 22(S1):S1–S49. <https://doi.org/10.12968/jowc.2013.22.sup1.s1>
4. Wilcox JR, Carter MJ, Covington S. Frequency of debridements and time to heal: a retrospective cohort study of 312744 wounds. *JAMA Dermatol*. 2013; 149(9):1050–1058. <https://doi.org/10.1001/jamadermatol.2013.4960>
5. Tettelbach W, Cazzell S, Reyzelman A, Sigal F, Caporusso J, Agnew P. A confirmatory study on the efficacy of dehydrated human amnion/chorion membrane dHACM allograft in the management of diabetic foot ulcers: a prospective, multicentre, randomised, controlled study of 110 patients from 14 wound clinics. *Int Wound J*. 2019; 16(1):19–29. <https://doi.org/10.1111/iwj.12976>
6. Wounds UK. Best practice statement: making day-to-day management of biofilm simple. Wounds UK. 2017. www.wounds-uk.com/resources/details/best-practice-statement-making-daytoday-management-biofilm-simple (accessed 22 June 2022)
7. Eliasson B, Ann-Mari F, Jönsson A, Apelqvist J. Debriding effect of amino acid-buffered hypochlorite on hard-to-heal wounds covered by devitalised tissue: pilot study. *J Wound Care*. 2021; 30(6):455–464. <https://doi.org/10.12968/jowc.2021.30.6.455>

Introducing a new approach to debridement and wound bed preparation



Leanne Atkin, Vascular Nurse Consultant, Mid Yorkshire Hospitals NHS Trust and University of Huddersfield

Debridement of devitalised tissue and wound biofilm is vital to promote healing. This article introduces an innovative debridement product, ChloraSolv Wound Debridement Gel, which is as effective as a blade but also selective, atraumatic and fast-acting and does not require specialist training. Its ease of use makes it suitable for all settings and staff.

Despite the wealth of knowledge on the importance and benefits of debridement in facilitating wound healing, there remains huge challenges in day-to-day practice. Barriers include lack of training, skills, confidence and competence, as well as even the time to consistently undertake the process on a regular basis. Easy debridement methods need to be available for all clinicians at the point of need for patients.

This article discusses debridement and the importance of devitalised tissue and biofilm reduction (or removal) in wound management and wound bed preparation. It identifies some of the barriers to debridement and considers how they can be overcome in clinical practice. It introduces a novel chemo-mechanical debridement gel (ChloraSolv, RLS Global AB, distributed by ConvaTec), which can facilitate debridement of devitalised tissue and mechanical biofilm removal without surgical or sharp debridement. The gel's mode of action is described, and information is given on its application and ease of use, including how it can also be used to enhance sharp debridement. The evidence on its efficacy is outlined, with consideration of the implications for practice. It is hoped that ChloraSolv will help reduce unwarranted variation in wound management.

Role of debridement

Debridement is an essential part of wound bed preparation and thus wound management, as it enables the normal process of tissue repair to occur.¹ Debridement is the process of removing adherent contaminated or dead tissue and bioburden/biofilm from the wound and its edges to facilitate and promote granulation-tissue formation and healing. It is a separate entity to wound cleansing.¹⁻²

According to a 2017 systematic review by Malone et al., 78% of hard-to-heal wounds harbour biofilms.³ However, the true prevalence is likely to be closer to 100%.⁴ Biofilm is embedded in wound-bed tissue, necrotic tissue, slough, exudate and debris, as well as within the dressing that has been removed.⁵ It can be present on the wound surface and deeper within the wound bed.⁶

Biofilms are complex microbial communities containing multiple microorganisms, which can include aerobic and anaerobic bacteria and fungi. Due to the formation of extracellular polymeric substances (EPS), the microorganisms are somewhat protected from and often tolerant to topical antiseptics, systemic antibiotics and host defences.⁷ Biofilm delays healing,⁸ and it increases the risk of localised, spreading and systemic infection.⁵

Biofilm management requires a multi-targeted approach to break this cycle,⁹ with debridement providing a window of opportunity for antibiofilm strategies to work, thereby helping to prevent biofilm reformation.¹⁰ Bianchi et al. recommend that all wound types, except arterial ulcers, should be sharp and/or mechanically debrided to remove biofilm,¹¹ which has been demonstrated to be effective in stimulating healing.¹²

Along with the management of the underlying wound aetiology, both devitalised tissue and biofilm need to be removed to expedite progression of the wound to healing.¹ Therefore, debridement is considered to be an integral part of wound bed preparation, and it should be incorporated into wound assessment and management frameworks such as Wound Hygiene,² TIME/TIMERS¹²⁻¹⁴ and the Triangle of Wound Assessment.¹⁵ These frameworks have been widely adopted into national and international wound-management protocols.

Wound bed preparation and the Wound Hygiene protocol should be implemented at every single dressing change, just as people follow personal and dental hygiene on a regular basis. The frequency of debridement is also key in enabling improved clinical outcomes in hard-

to-heal wounds.¹⁶ A 2016 study by Tettelbach et al. demonstrated that patients with hard-to-heal wounds were three times more likely to heal at 12 weeks when adequate debridement was performed.¹⁷

Failure to debride regularly will not only delay healing, but it can also have extremely negative consequences for the patient. A wealth of evidence has demonstrated the impact of hard-to-heal wounds on a patient's quality of life, many of whom live without any hope of healing or improvement.^{18–23} Delayed healing can increase the bioburden, causing patients pain and excess exudate, along with a greater likelihood of strikethrough, malodour, infection and associated psychosocial consequences.⁵

In countries such as the UK, a growth in population size and comorbidities and an increasing average age have led to an increase in the prevalence of wounds. This increases the economic burden on healthcare services,²⁴ particularly with greater demand for nursing resources.

Therefore, effective implementation of step 2 of the Wound Hygiene protocol and wound bed preparation at each dressing change requires that all nurses who manage wounds are able to debride. However, although there is an abundance of evidence to support the benefits of debridement in enhancing healing, in clinical practice, particularly in the community setting, it is not consistently undertaken by health professionals.²⁵

There are a large range of options, which vary in terms of their selectiveness, invasiveness, efficacy and training required, with each option having advantages and disadvantages. Types of debridement method include the following:¹

- Surgical debridement, which involves the use of surgical

instruments, usually by a surgeon (general, vascular, trauma or plastics) to remove the devitalised tissue

- Sharp debridement, which involves the use of a scalpel, scissors or curette to remove devitalised tissue. This can be performed by a range of medical specialists with the appropriate training and competence, such as tissue viability nurses, GPs, podiatrists and dermatologists, in all settings
- Mechanical debridement, which uses monofilament cloths/gloves/pads, polyester/polyurethane foams or microfibre pads, some of which are impregnated or can be moistened with various solutions, to soften and moisturise and to remove slough and devitalised tissue, rather than dry eschar, from the wound bed
- Hydrosurgery, which is the application of a high-pressure liquid solution to cause a lavage/sharp-debridement effect
- Enzymatic debridement, which uses proteolytic enzymes to hydrolyse peptide bonds for the removal of non-viable tissue via a moist environment. As such, it is not suitable for dry wounds
- Biological debridement, which is the use of greenbottle fly larvae to ingest devitalised tissue and microbes and, therefore, stimulate wound healing
- Ultrasound, which applies low-frequency energy to selectively debride devitalised tissue. This requires specialist training using relatively high-cost equipment
- Autolytic debridement, which uses the body's inherent ability to remove non-viable tissue, usually by applying a moist wound-healing dressing. This requires limited technical skill, but it may

take weeks to be effective when used as the only debridement strategy. It can also increase the risk of invasive infection and periwound maceration.² Autolytic debridement has varied efficacy in controlling biofilm,⁵ which evidence suggests is due to the biofilm residing on the wound surface and deeper within the wound bed.⁶ Therefore, rapid debridement strategies are required for effective removal.^{26–27}

There are no optimal methods of debridement for devitalised tissue and biofilm management, and clinical evidence does not support one approach over another.⁵ Their effectiveness will depend on the implementation of wound bed preparation, plus use of an antibiofilm strategy at an appropriate stage of the biofilm cycle.¹⁰ Any debridement intervention should be within the competency of the health professional undertaking it.

Surgical debridement is considered the gold standard but often requires general anaesthesia, and so admission to secondary care is usually necessary. Therefore, to enable the most cost-effective and frequent debridement to occur, sharp debridement is considered the standard of care for the removal of devitalised tissue and biofilm management. It is a fast and efficient method of preventing biofilm from reaching maturity, thus providing a window of therapeutic opportunity for antimicrobial measures and wound bed preparation.^{28–29} Sharp debridement also penetrates into both the superficial and deeper areas of the wound, ensuring a more extensive removal of the devitalised tissue and biofilm. However, sharp debridement requires specialist skills, training and competencies and, therefore, is not readily available at the point of need, certainly not at each dressing change.

Patient reluctance to undergo debridement can also pose challenges, particularly as some methods can be painful. Patients too need to be provided with education on the importance of debridement and what to expect, as they often state that their wound looks worse after the procedure, due to the occurrence of bleeding and more depth becoming visible after the devitalised tissues have been removed.

The risks of sharp debridement include damage of blood vessels, nerves and tendons, if incorrectly performed. This results in even those health professionals appropriately trained being apprehensive about the technique,³⁰ particularly as it can be time-consuming.

Even the simple mechanical debridement methods, which are relatively safe and easy to perform, are not readily considered or implemented.³¹ This is possibly due to a lack of education and/or inclusion of debridement pads/wipes on wound-care formularies. Generalist nurses often consider debridement to be beyond their competency, assuming it should only be undertaken by a specialist. Mechanical debridement methods are much slower than sharp debridement and not particularly effective on hard eschar and adherent slough.⁹

The use of surfactant cleansing solutions and gels, which often contain antimicrobial agents,

has been demonstrated to remove biofilm and prevent its re-formation.³³⁻³⁴ However, these should be used in combination with debridement,⁴ and they may require time periods for soaking, depending on the level of slough and devitalised tissue present.

Therefore, although there is an abundance of evidence to enhance the benefits of debridement in promoting healing, in clinical practice, particularly in the community setting, it is not consistently undertaken by health professionals. Therefore, the development of products that enable regular, convenient and safe debridement is desirable. With the introduction of this novel chemo-mechanical debridement treatment (ChloraSolv), an alternative approach can be considered to enable fast, safe and effective debridement that is atraumatic, requires minimal training and has been demonstrated to be as efficacious as sharp debridement.³⁵

ChloraSolv

ChloraSolv is a new category of debridement product: a chemo-mechanical wound debridement gel, indicated for debridement of leg ulcers and diabetic foot ulcers. It gently softens and removes devitalised tissue and biofilm, is selective and does not cause any trauma or bleeding.³⁵⁻³⁶ The treatment can be applied with minimal training. ChloraSolv can be used as an adjunct to sharp debridement, enhancing its performance, or on its own, with

damp gauze, to aid removal.³⁵ Being a gel, ChloraSolv softens tissue and can reach pockets of devitalised tissue that can be hard to access with a blade or gauze pad alone.

ChloraSolv is an amino acid-buffered hypochlorite gel that consists of two components: a carboxymethylcellulose gel, which contains amino acids, and sodium hypochlorite solution. Sodium hypochlorite is known to have properties that soften devitalised tissue,³⁶ and it has been recommended⁵ for use as an antimicrobial cleansing solution for the eradication of *Pseudomonas aeruginosa* and meticillin-resistant *Staphylococcus aureus*,³⁷ common biofilm bacteria found in wounds.³⁸

Application

ChloraSolv is easy to use and requires minimal training. It is an amino acid-buffered hypochlorite gel that consists of two components, which are mixed in the syringe at the point of use to form a high pH-buffered gel containing 0.45% sodium hypochlorite (Figure 1 and Box 1). A thin layer of the gel is then applied with the syringe plunger over the whole wound bed and left to act for 2–5 minutes, during which time it softens the devitalised tissue and acts on biofilm. The devitalised tissue and debris can then be gently removed with a blunt instrument, debridement pad or any wipe, and the wound area rinsed and wiped dry. The process is then immediately repeated to remove additional

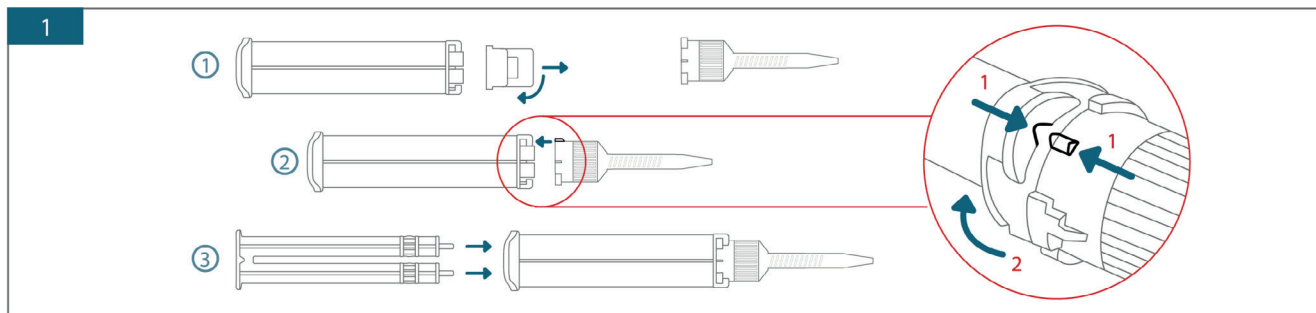


Figure 1. Assembling the syringe (step 1)

loosened devitalised tissue or biofilm. These steps are outlined in *Figure 2*.

The treatment can be repeated one or two times per week until there is no more devitalised tissue in the wound, up to a maximum of 24 weeks. Once the devitalised tissue has been removed, the standard Wound Hygiene protocol and wound bed preparation should be continued to facilitate wound healing.

Due to its low concentration of sodium hypochlorite (0.45%), ChloraSolv is biocompatible for short durations,³⁹ making it safe and non-irritating to healthy tissue and, unlike sharp debridement, not at risk of causing any bleeding or trauma. ChloraSolv seems to be well tolerated, receiving a 'good' or 'very good' rating on the experience of using it,³⁵ and it does not routinely require any analgesia.

Tissue debridement mode of action

ChloraSolv has a dual action of tissue debridement and an antimicrobial and antibiofilm effect.

ChloraSolv creates a highly alkaline pH and oxidative local environment for softening devitalised tissue. The tissue-softening effect of sodium hypochlorite has been known for over

Box 1. Process of application (steps 1–10)

1. Assemble the syringe and mix the components together
2. Apply a thin layer of the gel using the syringe plunger (the product should cover the wound area completely when applied)
3. Leave the gel on the wound to act for 2–5 minutes, during which time it softens the devitalised tissue and acts on biofilm
4. Remove loosened devitalised tissue, using a gentle scraping action with a blunt instrument or debridement pad/cloth or other wipe
5. Rinse the wound area with water or isotonic saline solution and wipe dry (sterile water is not a requirement)
6. Finish the procedure with a second application of the gel directly onto the wound area to completely clean the wound bed
7. Leave the gel on the wound for 2–5 minutes
8. Remove loosened necrotic tissue, using a gentle scraping action with a blunt instrument or debridement pad/cloth or other wipe
9. Rinse the wound area with water or isotonic saline solution and wipe dry
10. Protect the wound with a bandage or dressing that is appropriate for its characteristics

a century,^{40–41} with high-pH sodium hypochlorite solutions having a greater tissue-dissolving capacity than lower-pH solutions.^{42–44} The high pH results in short-acting and localised high concentrations of hydroxide for the hydrolysis of biological polymers (whereby water molecules are used to split the polymers into monomers) in devitalised tissue (mainly protein) and biofilm (mainly polysaccharides plus protein and extracellular DNA). Hypochlorite

also has an oxidative action on devitalised tissue, biofilm structure and microbial cell components, killing bacterial and fungal pathogens. A high pH ensures that hypochlorite (ClO^-) is the active chlorine species. Appropriate hypochlorite solutions, used selectively, have been widely adopted in dental applications as root canal irrigants and cleansers.^{43,45}

The alkalinity will diminish during and following the treatment,³⁵ when the

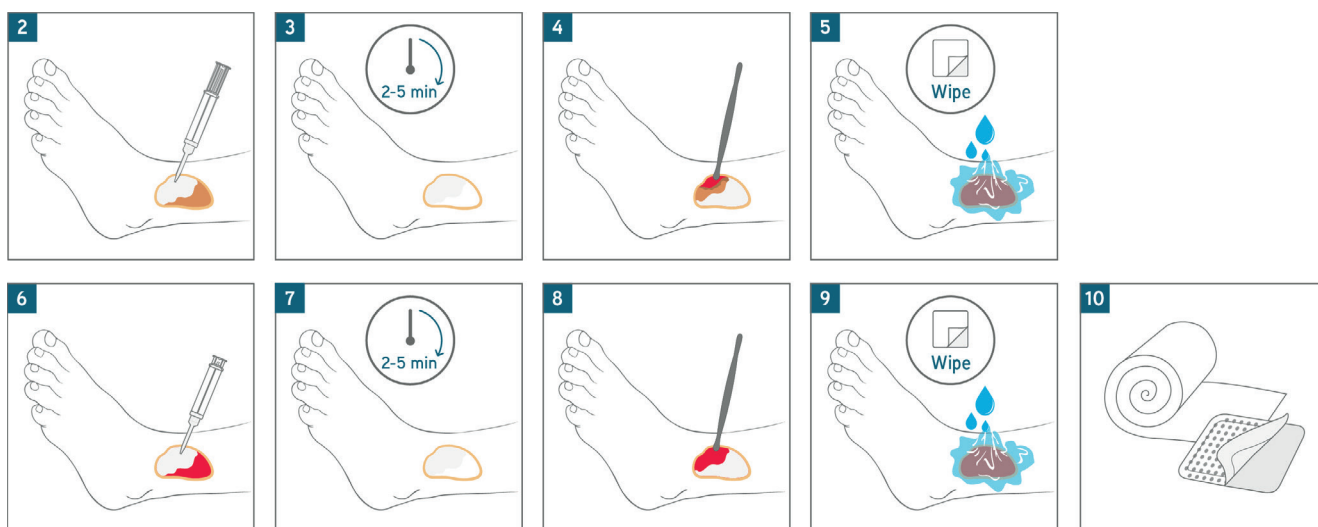


Figure 2. Instructions for use (steps 2–10)

product, along with softened tissue and killed microbes, is removed and becomes neutralised. This is due to the high buffering capacity of human tissue and fluids.⁴⁶

The clinical evidence on ChloraSolv, including the case studies included in this document, has shown no evidence of any irritation or pain that might be associated with short-term, localised high alkalinity.

Antimicrobial and antibiofilm mode of action

The sodium hypochlorite in ChloraSolv has a broad spectrum and antifungal activity to facilitate wound cleansing, as demonstrated in standard antimicrobial susceptibility testing.³⁵ The antibiofilm activity of ChloraSolv has been demonstrated against *Pseudomonas aeruginosa* and *Staphylococcus aureus* in standard biofilm-eradication tests, where significant biofilm reductions were observed 30 seconds after application, with complete killing of the biofilm bacteria occurring after 2 minutes *in vitro*.⁴⁷

Evidence

ChloraSolv is a novel chemo-mechanical wound debridement gel that has been shown to soften devitalised tissue, facilitate removal of devitalised tissue in clinical studies (Table 1),³⁵⁻³⁶ rapidly remove biofilm *in vitro*⁴⁷ and have broad-spectrum antimicrobial activity.

A randomised controlled study undertaken on 34 patients in Sweden compared ChloraSolv with standard of care in the treatment of diabetic foot ulcers for 12 weeks.³⁶ Participants were followed up for a total of 24 weeks from the start of treatment. The wounds were cleansed and debrided at least weekly. A faster change from black or yellow devitalised tissue to purulence and red granulation tissue was observed in the ChloraSolv

treatment group compared with those receiving standard of care alone. The investigators observed that ChloraSolv is a safe treatment for infected diabetic foot ulcers, with healing times being shorter in the ChloraSolv group during the first 2 months of the study, but not after 12 weeks and 24 weeks. They proposed that the application of ChloraSolv during the weekly treatments was likely to be more efficacious in the early phases of the treatment.

A single-arm multicentre pilot investigation was undertaken in Sweden on 57 patients with hard-to-heal lower-limb wounds of various aetiologies.³⁵ ChloraSolv was applied weekly for 5 weeks, and follow-up was performed after 12 weeks from baseline (7 weeks after the last

treatment). Patients were managed with their initial standard of care according to national guidelines. At the end of the 5-week period, a 73% reduction in devitalised tissue was noted, with a good correlation between the reduction of devitalised tissue and a reduction in wound size. Only seven participants had required sharp debridement of the wound as an adjunct to the ChloraSolv treatment during the investigation period. The investigators determined that this indicated a decreased requirement for sharp debridement, without damaging the underlying tissue. Some degree of pain was reported in relation to ChloraSolv, but 90% of patients given the gel rated pain during debridement as 'good' or 'very good'. A reduction in devitalised tissue was noted after the first treatment, which continued

Table 1. Evidence for ChloraSolv

Study	Bergqvist et al. ³⁶	Eliasson et al. ³⁵
Study design	Randomised controlled trial	Open-label, single-arm, pre-market pilot investigation
Sample	34 patients with infected hard-to-heal diabetic foot ulcers, equally randomised to ChloraSolv or standard of care ⁵⁰	57 patients with hard-to-heal ulcers on the lower limb with ≥50% devitalised tissue, 35 patients having leg ulcers and 22 foot ulcers
Follow-up period	Treatment period of 12 weeks; final follow-up of 24 weeks after initiation	Treatment period of 5 weeks; final follow-up of 12 weeks after initiation
Results	<ul style="list-style-type: none"> At week 5, statistically significant reduction in ulcer size compared with standard of care ($p=0.016$ relative reduction, $p=0.024$ absolute reduction) Weekly relative reduction in ulcer size: 19.4% vs 11.7% for the ChloraSolv and standard-of-care groups, respectively Reduction in ulcer size was statistically significant for ChloraSolv after 2 weeks ($p=0.026$) and after 8 weeks ($p=0.0023$) for standard of care At week 9, ulcers in seven patients in the ChloraSolv group had healed vs one patient in the standard-of-care group 	<ul style="list-style-type: none"> At week 5, a median 72.7% decrease in devitalised tissue (for 71.4% of patients, this was a ≥50% reduction) At week 12, a median 84.4% decrease in devitalised tissue
Conclusion	ChloraSolv is effective, particularly in the early phases of infected diabetic foot ulcers	ChloraSolv effectively softens and removes devitalised tissue

throughout the 5 weeks, along side the need for sharp debridement.³⁵

Benefits

ChloraSolv provides the advantages associated with sharp and mechanical debridement, without the risks related to sharp debridement, such as bleeding and damage to underlying tissue structures, and it is designed to be effective with adherent slough and hard eschar. It is an easy product to use, requiring minimal training, and its fast action should enable patients to see the benefits of using the treatment and provide hope, with the prospect that their wound might heal. Use of ChloraSolv can be easily incorporated into a wound-management protocol, such as Wound Hygiene. *Figures 3 and 4* provide examples of outcomes achieved following use of ChloraSolv in clinical practice.

Implications for practice

There is a large amount of evidence to support the healing benefits of regular debridement in hard-to-heal wounds.¹⁴ Regular implementation of debridement as part of a protocol of care, such as Wound Hygiene or TIMERS, can help standardise care and reduce unwarranted variations in patient outcomes. This can reduce the health-economic burden of wound care. However, standard sharp debridement requires specialist training, which limits the number of health professionals with the necessary competencies to undertake it. Therefore, it is not available at the point of need on a day-to-day basis. Use of ChloraSolv can enable the patient to receive regular, safe and effective debridement at the point of care in all settings, as well as to manage devitalised tissue and biofilm effectively, which could save tissue viability nurses' time.

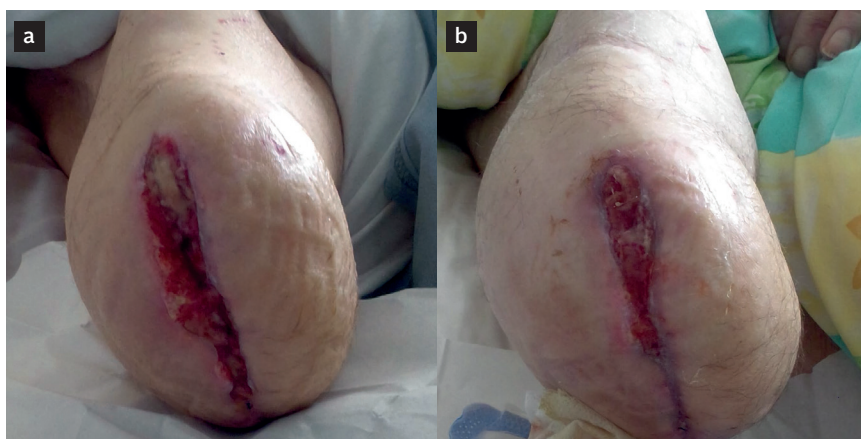

Figure 3. Example of debridement with ChloraSolv on a non-healing stump wound: before the initial use of ChloraSolv, the patient was experiencing pain and discomfort during debridement and was unable to have a prosthesis fitted (a); after 3 weeks of twice-weekly debridement with ChloraSolv, the gel enabled quick and painless removal of the devitalised tissue and full healing occurred at week 5 (b)

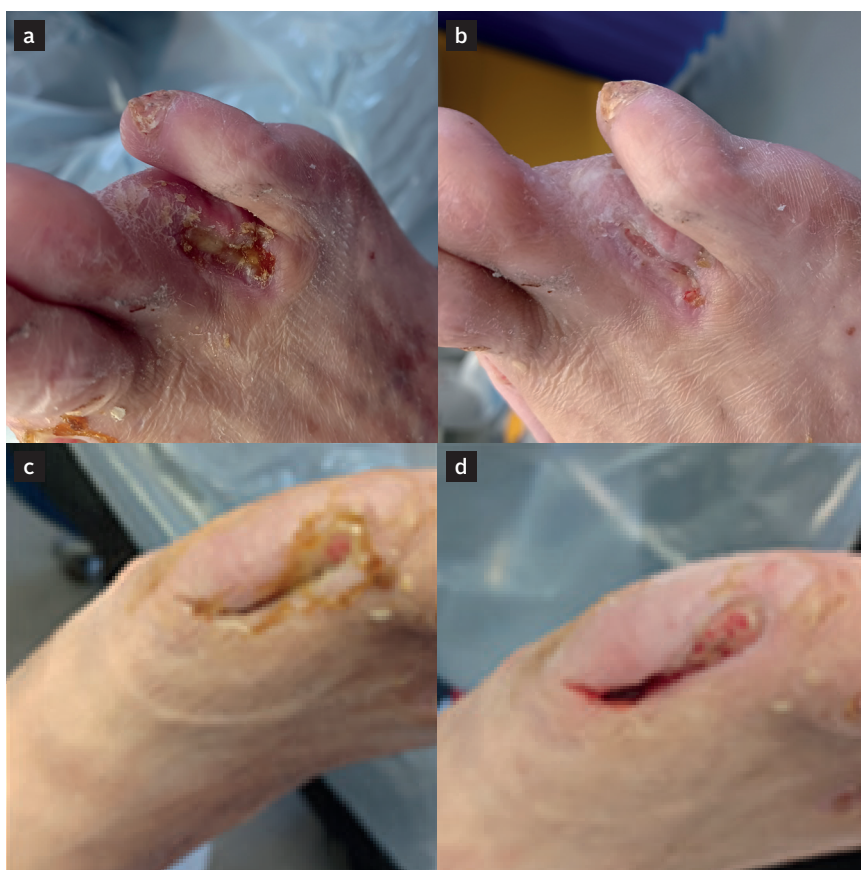

Figure 4. Example of debridement with ChloraSolv on a diabetic foot in which the first and fourth digits had been amputated due to infection and necrosis (a and c); following application of two syringes of ChloraSolv at a single visit, a clean wound bed was achieved (b and d); the consultant had requested larvae, but these were not required; 2 weeks later, the wound on the amputation site of the fourth digit had healed, while the wound bed where the first digit had been remained clean and was progressing towards healing

This may expedite faster healing, reduce antibiotic resistance⁴⁸ and prevent hospital admissions, which will reduce the economic burden of wounds and improve patients' quality of life.⁴⁹

Conclusion

There are well-documented barriers and challenges to wound debridement. Innovative treatments need to be considered in wound management to reduce unwarranted variation and provide the right care for the right patient at the right time. ChloroSolv is a novel alternative for debridement; it has a fast acting and short application time and effectively debrides devitalised tissue and removes biofilm. Use of ChloroSolv, as a safe, non-irritant, easy-to-use device, can enable regular debridement of devitalised tissue and biofilm at the point of need for patients' wounds.

References

1. Strohal R, Dissemmond J, Jordan O'Brien J et al. Debridement: an updated overview and clarification of the principle role of debridement. *J Wound Care*. 2013; 22(S1):S1–S49. <https://doi.org/10.12968/jowc.2013.22.s1>
2. Murphy C, Atkin L, Swanson T et al. Defying hard-to-heal wounds with an early antibiofilm intervention strategy: wound hygiene. *J Wound Care*. 2020; 29(S3b):S1–S26. <https://doi.org/10.12968/jowc.2020.29.s3b.s1>
3. Malone M, Bjarnsholt T, McBain AJ et al. The prevalence of biofilms in chronic wounds: a systematic review and meta-analysis of published data. *J Wound Care*. 2017; 26(1):20–25. <https://doi.org/10.12968/jowc.2017.26.1.20>
4. World Union of Wound Healing Societies. Strategies to reduce practice variation in wound assessment and management: the T.I.M.E. clinical decision support tool. Wounds International. 2020. www.woundsinternational.com/resources/details/strategies-reduce-practice-variation-wound-assessment-and-management-time-clinical-decision-support-tool (accessed 20 June 2022)
5. International Wound Infection Institute. Wound infection in clinical practice international consensus update. Wounds International. 2022. www.woundsinternational.com/resources/details/wound-infection-in-clinical-practice-principles-of-best-practice (accessed 20 June 2022)
6. Kirketerp-Møller K, Stewart P, Bjarnsholt T et al. The zone model: a conceptual model for understanding the microenvironment of chronic wound infection. *Wound Repair Regen*. 2020; 28(5):593–599. <https://doi.org/10.1111/wrr.12841>
7. Wolcott RD, Rhoads DD. A study of biofilm-based wound management in subjects with critical limb ischaemia. *J Wound Care*. 2008; 17:145–154. <https://doi.org/10.12968/jowc.2008.17.4.28835>
8. Metcalf D, Bowler P. Biofilm delays wound healing: a review of the evidence. *Burns Trauma*. 2013; 1(1):5–12. <https://doi.org/10.4103/2321-3868.113329>
9. Wounds UK. Best practice statement: making day-to-day management of biofilm simple. Wounds UK. 2017. www.wounds-uk.com/resources/details/best-practice-statement-making-day-to-day-management-biofilm-simple (accessed 20 June 2022)
10. Wolcott RD, Rumbaugh KP, James G et al. Biofilm maturity studies indicate sharp debridement opens a time-dependent therapeutic window. *J Wound Care*. 2010; 19(8):320–328. <https://doi.org/10.12968/jowc.2010.19.8.77709>
11. Bianchi T, Wolcott RD, Peghetti A et al. Recommendations for the management of biofilm: a consensus document. *J Wound Care*. 2016; 25(6):305–317. <https://doi.org/10.12968/jowc.2016.25.6.305>
12. Atkin L, Bucko Z, Montero EC et al. Implementing TIMERS: the race against hard-to-heal wounds. *J Wound Care*. 2019; 28(S3a):S1–50. <https://doi.org/10.12968/jowc.2019.28.s3a.s1>
13. World Union of Wound Healing Societies. Position document: management of biofilm. Wounds International. 2016. www.woundsinternational.com/resources/details/position-document-management-biofilm (accessed 20 June 2022)
14. Schultz GS, Sibbald RG, Falanga V et al. Wound bed preparation: a systematic approach to wound management. *Wound Repair Regen*. 2003; 11(S1):S1–S28. <https://doi.org/10.1046/j.1524-475X.11.s2.1.x>
15. Dowsett C, Protz K, Drouad M, Harding KG. Triangle of wound assessment made easy. Wounds International. 2015. www.woundsinternational.com/resources/details/triangle-of-wound-assessment-made-easy (accessed 20 June 2022)
16. Wilcox JR, Carter MJ, Covington S. Frequency of debridements and time to heal: a retrospective cohort study of 312 744 wounds. *JAMA Dermatol*. 2013; 149(9):1050–1058. <https://doi.org/10.1001/jamadermatol.2013.4960>
17. Tettellbach W, Cazzell S, Reyzelman A, Sigal F, Caporosso J, Agnew P. A confirmatory study on the efficacy of dehydrated human amnion/chorion membrane dHACM allograft in the management of diabetic foot ulcers: a prospective, multicentre, randomised, controlled study of 110 patients from 14 wound clinics. *Int Wound J*. 2019; 16(1):19–29. <https://doi.org/10.1111/iwj.12976>
18. Arshad M, Arshad S, Arshad S et al. The quality of life in patients with diabetic foot ulcers. *J Diabetes Metab*. 2020; 11(2):1–2. <https://doi.org/10.35248/2155-6156.20.11.e101>
19. González-Consuegra RV, Verdú J. Quality of life in people with venous leg ulcers: an integrative review. *J Adv Nurs*. 2011; 67(5):926–944. <https://doi.org/10.1111/j.1365-2648.2010.05568.x>
20. Gorecki C, Brown JM, Nelson EA et al. Impact of pressure ulcers on quality of life in older patients: a systematic review. *J Am Geriatr Soc*. 2009; 57(7):1175–1183. <https://doi.org/10.1111/j.1532-5415.2009.02307.x>
21. Polikandrioti M, Vasilopoulos G, Koutelekos I et al. Quality of life in diabetic foot ulcer: associated factors and the impact of anxiety/depression and adherence to self-care. *Int J Low Extrem Wounds*. 2020; 19(2):165–179. <https://doi.org/10.1177/1537434619900415>
22. Herber OR, Schnepf W, Rieger MA. A systematic review on the impact of leg ulceration on patients' quality of life. *Health Qual Life Outcomes*. 2007; 5(1):44. <https://doi.org/10.1186/1477-7525-5-44>
23. Upton D, Solowiej K, Hender C, Woo KY. Stress and pain associated with dressing change in patients with chronic wounds. *J Wound Care*. 2012; 21(2):53–61. <https://doi.org/10.12968/jowc.2012.21.2.53>
24. Guest JF, Fuller GW, Vowden P. Cohort study evaluating the burden of wounds to the UK's National Health Service in 2017/2018: update from 2012/2013. *BMJ Open*. 2020; 10(12):e045253. <https://doi.org/10.1136/bmjopen-2020-045253>
25. Fumarola S. The effect of a new debridement technique on patient wellbeing. *Wounds UK*. 2012; 8(4):84–89. https://lohmman-rauscher.co.uk/downloads/clinical-evidence/ds019-the_effect_of_a_new.pdf (accessed 20 June 2022)
26. Leaper DJ, Schultz G, Carville K, Fletcher J, Swanson T, Drake R. Extending the TIME concept: what have we learned in the past 10 years? *Int Wound J*. 2012; 9(S2):S1–S19. <https://doi.org/10.1111/j.1742-481X.2012.01097.x>
27. Wolcott R. Economic aspects of biofilm-based wound care in diabetic foot ulcers. *J Wound Care*. 2015; 24(5):189–194. <https://doi.org/10.12968/jowc.2015.24.5.189>
28. Wolcott RD, Kennedy JP, Dowd SE. Regular debridement is the main tool for maintaining a healthy wound bed in most chronic wounds. *J Wound Care*. 2009; 18(2):54–56. <https://doi.org/10.12968/jowc.2009.18.2.38743>
29. Hurlow J, Bowler PG. Potential implications of biofilm in chronic wounds: a case series. *J Wound Care*. 2012; 21(3):109–119. <https://doi.org/10.12968/jowc.2012.21.3.109>
30. Murphy C, Atkin L, Hurlow J, Swanson T, de Céniga MV. Wound hygiene survey: awareness, implementation, barriers and outcomes. *J Wound Care*. 2021; 30(7):582–590. <https://doi.org/10.12968/jowc.2021.30.7.582>
31. Barrett S, Dark J, Dowsett C et al. Best practice recommendations: wound preparation by cleansing and debridement using Alprep pad. Wounds UK. 2022. www.wounds-uk.com/resources/details/wound-preparation-by-cleansing-and-debridement-using-alprep-pad (accessed 20 June 2022)
32. Murphy C, Atkin L, Vega de Céniga M, Weir D, Swanson T. International consensus document: embedding wound hygiene into a proactive wound healing strategy. *J Wound Care*. 2022; 31(S1):S24. <https://doi.org/10.12968/jowc.2022.31.S1.S24>
33. Braun M, McGrath A, Downie F. Octenilin range made easy. Wounds UK. 2013; 9(4). www.wounds-uk.com/resources/details/octenilin-range-made-easy (accessed 20 June 2022)
34. Bradbury S, Fletcher J. Prontosan made easy. Wounds International. 2011; 2(2). www.woundsinternational.com/resources/details/prontosan-debridement-pad-made-easy (accessed 20 June 2022)
35. Eliasson B, Ann-Mari F, Jönsson A, Apelqvist J. Debriding effect of amino acid-buffered hypochlorite on hard-to-heal wounds covered by devitalised tissue: pilot study. *J Wound Care*. 2021; 30(6):455–464. <https://doi.org/10.12968/jowc.2021.30.6.455>
36. Bergqvist K, Almhöjd U, Herrmann I, Eliasson B. The role of chloramines in treatment of diabetic foot ulcers: an exploratory multicentre randomised controlled trial. *Clin Diabetes Endocrinol*. 2016. 2(1):6. <https://doi.org/10.1186/s40842-016-0026-8>
37. McMahon R, Salamone AB, Poleon S, Bionda N, Salamone J. Efficacy of wound cleansers on wound-specific organisms using *in vitro* and *ex vivo* biofilm models. *Wound Manage Prev*. 2020; 66(11):31–42. <https://doi.org/10.25270/wmp.2020.11.3142>
38. Gjødsbøl K, Christensen JJ, Karlsmark T, Jørgensen B, Klein BM, Krogfelt KA. Multiple bacterial species reside in chronic wounds: a longitudinal study. *Int Wound J*. 2006; 3(3):225–231. <https://doi.org/10.1111/j.1742-481X.2006.00159.x>
39. Estrela C, Estrela CRA, Barbin EL, Spanó JCE, Marchesan MA, Pécora JD. Mechanism of action of sodium hypochlorite. *Braz Dent J*. 2002; 13(2):113–117. <https://doi.org/10.1590/S0103-64402002000200007>
40. Taylor HD, Austin JH. The solvent action of antiseptics on necrotic tissue. *J Exp Med*. 1918; 27(1):155–164. <https://doi.org/10.1084/jem.27.1.155>
41. Austin JH, Taylor HD. Behavior of hypochlorite and of chloramine-t solutions in contact with necrotic and normal tissues *in vivo*. *J Exp Med*. 1918; 27(5):627–633. <https://doi.org/10.1084/jem.27.5.627>
42. Jungbluth H, Marending M, De-Deus G, Sener B, Zehnder M. Stabilizing sodium hypochlorite at high pH: effects on soft tissue and dentin. *J Endod*. 2011; 37(5):693–696. <https://doi.org/10.1016/j.joen.2011.02.019>
43. Rossi-Fedele G, Guastalli AR, Doğramacı EJ, Steier L, De Figueiredo JAP. Influence of pH changes on chlorine-containing endodontic irrigating solutions. *Int Endod J*. 2011; 44(9):792–799. <https://doi.org/10.1111/j.1365-2591.2011.01911.x>
44. Christensen CE, McNeal SF, Eleazer P. Effect of lowering the pH of sodium hypochlorite on dissolving tissue *in vitro*. *J Endod*. 2008; 34(4):449–452. <https://doi.org/10.1016/j.joen.2008.01.001>
45. Zehnder M, Kosicki D, Luder H et al. Tissue-dissolving capacity and antibacterial effect of buffered and unbuffered hypochlorite solutions. *Oral Surg Oral Med Pathol Oral Radiol Endod*. 2002; 94(6):756–762. <https://doi.org/10.1067/moe.2002.128961>
46. Proksch E. Buffering capacity. *Curr Probl Dermatol*. 2018; 54(11):11–18. <https://doi.org/10.1159/000489513>
47. Ahlenius M, Olsson S, Åberg M, Schmidtchen A. Fast and complete eradication of biofilm by wound debridement gel. Poster presentation at EWMA 2021
48. Wounds UK. Best practice statement: antimicrobial stewardship strategies for wound management. Wounds UK. 2020. www.wounds-uk.com/resources/details/best-practice-statement-antimicrobial-stewardship-strategies-wound-management
49. Adderley U. National Wound Care Strategy update: from strategy development to implementation. Wounds UK. 2022; 18(1):104–105. www.wounds-uk.com/journals/issue/657/article-details/national-wound-care-strategy-update-strategy-development-implementation (accessed 22 June 2022)
50. Game FL, Hinchliffe RJ, Apelqvist J et al. Specific guidelines on wound and wound-bed management 2011. *Diabetes Metab Res Rev*. 2012; 28(S1):S232–S233. <https://doi.org/10.1002/dmrr.2250>

Implementation in practice: case studies



Case studies are presented here by a tissue viability nurse consultant and an advanced podiatrist demonstrating the use of ChloraSolv in clinical practice. The first set of cases is from a community setting, where the tissue viability nurse and district nurse successfully used the product to fully debride hard-to-heal leg ulcers in patients who mostly had been unable to tolerate other forms of debridement. The second set illustrates its use in a podiatry clinic, where the gel removed dry, adherent slough.

‘These case studies show that ChloraSolv can be used by any health professional to achieve a clean wound bed’

Case studies 1–3: leg ulcers



Joy Tickle, Tissue Viability Nurse Consultant, Isle of Wight NHS Trust, UK

Case study 1: leg ulcer, traumatic injury

Following a fall at home, a 74-year-old woman incurred a traumatic injury on her left lower limb. She self-treated the wound, but when the wound had still not healed 3 weeks later, she presented at her local GP.

The patient had a history of venous disease and inflammatory bowel disease, which was treated with steroid therapy during periods of exacerbation (steroid therapy can impede wound healing).¹

The wound was treated at the practice nurse (PN) clinic. The PN performed a holistic patient assessment including vascular (Doppler) and wound assessments. The PN calculated that the patient's ankle brachial pressure index (ABPI) was 0.9. It was considered that the trauma had resulted in a wound that failed to heal due to venous disease.

The PN, in consultation with the GP, initiated the following treatment:

- Cleansing with normal saline
- Application of a wound dressing
- Reduced compression therapy.

The PN was unable to debride the wound, as the patient was unable to tolerate any form of autolytic, mechanical or sharp debridement, even simple soft pads.

Given the patient's history of venous disease, a reduced compression bandaging system was applied to assist venous return, reduce limb oedema and promote healing.

Reduced compression was selected as the patient was unable to tolerate full compression, finding it too painful.

Unfortunately, the wound failed to progress towards healing, most likely due to the patient's inability to tolerate full compression and any form of debridement, which hindered wound bed preparation. Following consultation with a tissue viability nurse (TVN), a variety of primary wound dressings were used to promote healing, but the wound still did not improve. The patient experienced episodes of local wound infection, with clinical signs of erythema, increased pain and exudate, and malodour. Antimicrobial dressings (silver and medical-grade honey) were selected for treatment, based on clinical judgement and the formulary listing. On two occasions, the wound infection became systemic, with symptoms of patient malaise, pyrexia, increased wound pain and size, and purulent exudate. Antibiotics were prescribed, based on a microbiology report.

Treatment

Some 21 weeks after the patient was first treated by the practice nurse clinic, the TVN and PN undertook a joint patient visit to perform a comprehensive holistic assessment.

The wound, which was shallow, was circumferential, measuring 8x4cm. The wound bed comprised 20% necrotic tissue, 60% slough and 20% granulation tissue. It was producing a high volume of purulent, thick

exudate, and the wound edges on the back of the lower limb were excoriated and surrounded by necrotic tissue (*Figure 1*). There were clinical signs of local infection: wound malodour, increased exudate volume, erythema and increased pain. However, the main issue for the patient was the discomfort, with her self-reported pain visual analogue score (VAS) being 6/10, where 10 represented the highest level of pain.

The holistic assessment also revealed that the wound was negatively impacting the patient's quality of life. She reported that it was causing her anxiety and loss of sleep, leading to low mood and loss of appetite—all factors that can hinder wound healing.² She was reluctant to leave the house or receive visitors at home for fear of exudate leakage from the dressing, which would be embarrassing for her.

Following consultation with the patient, the TVN's wound-management objectives were to:

- Remove the devitalised tissue from the wound bed
- Reduce bioburden and infection
- Promote granulation and epithelial tissue formation.

The patient's treatment objectives were to:

- Promote comfort and reduce pain
- Ensure that wound cleansing and debridement were atraumatic
- Reduce the high exudate volume and thus prevent leakage

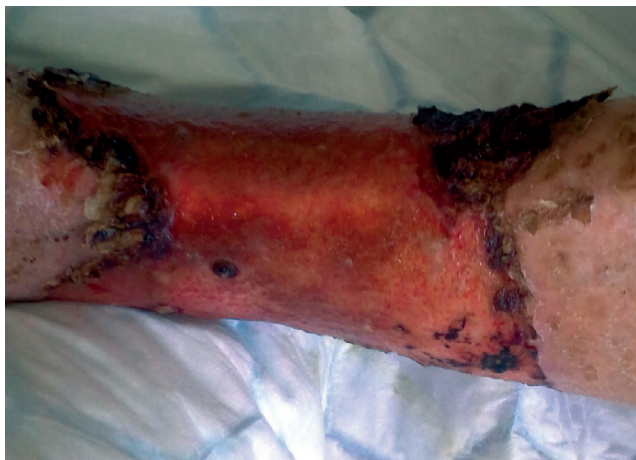

Figure 1. Wound before first application of ChloraSolv

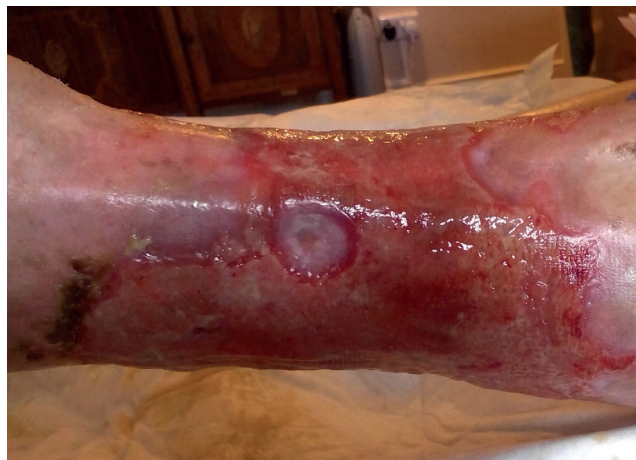

Figure 2. Wound after application of ChloraSolv on day 1

- Be able to perform activities of daily living.

Care was provided by both the PN and TVN. With the patient's consent, the TVN introduced ChloraSolv into the treatment regimen. It was applied by either the TVN or the PN, depending on who was undertaking the home visit. ChloraSolv was gently applied onto the wound bed, held in place with soft gauze for 2 minutes and then rinsed off with saline.

Patient outcome

Following the initial application, most of the eschar around the wound edges had softened and could be gently removed with the saline and gauze. After the second application of ChloraSolv immediately afterwards, all the eschar, plus any remaining slough and necrotic tissue, were removed, leaving a clean wound bed (Figure 2). The patient was able to tolerate the procedure, finding it atraumatic. Both the PN and TVN found ChloraSolv easy to use, with the entire procedure taking 10 minutes at most, and were impressed with its effectiveness. The wound was covered with Aquacel Extra dressing (ConvaTec) and compression therapy.

ChloraSolv was applied at the next patient visit 3 days later, as

25% slough had recurred on the wound bed, which was producing a moderate volume of serous exudate. Following two consecutive applications of ChloraSolv, all the slough was removed, again resulting in a clean wound bed (80% granulation tissue and 20% epithelial tissue) (Figure 3). No devitalised tissue has appeared on the wound bed since then, and the wound edges and periwound skin have remained healthy. The clinical signs of infection and high bioburden disappeared.

ChloraSolv was no longer used after this, with the PN and TVN simply cleansing the wound bed with saline, as this was all the patient could tolerate. Wound dressings were changed twice weekly. Use of compression was continued.

Patient experience

This rapid improvement in the condition of the wound bed, which was achieved without additional pain, was highly motivating for the patient. She was extremely pleased with the outcome, as the elimination of devitalised tissue meant there was no more malodour and a reduction in exudate volume, with leakage no longer being an issue. Her pain had reduced considerably. As a result, she was more confident to go out and socialise.

Health professionals' perspective

The PN was also extremely pleased with the clinical outcome, which was achieved without the need for a blade. She was impressed by both the ease of use and effectiveness of ChloraSolv, particularly as it does not require specialist training and can be safely applied, regardless of clinical experience. Both the TVN and PN regard ChloraSolv as a quick, simple and effective method of debridement that promotes healing and can be used by a wide skill-mix of staff in all care settings.

References

1. Carolina E, Kato T, Khanh V et al. Glucocorticoid impaired the wound healing ability of endothelial progenitor cells by reducing the expression of CXCR4 in PGE2 pathway. *Front Med (Lausanne)*. 2018; 5:276. <https://doi.org/10.3389/fmed.2018.00276>
2. House SL. Psychological distress and its impact on wound healing: an integrative review. *J Wound Ostomy Continence Nurs*. 2015; 42(1):38–41. <https://doi.org/10.1097/WON.0000000000000080>

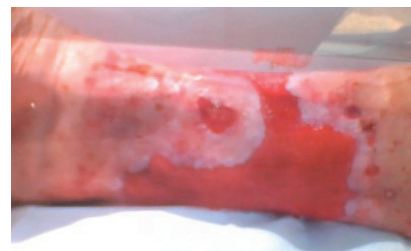

Figure 3. Wound 14 days after first application of ChloraSolv, with the wound bed still clean

Case study 2: leg ulcer, mixed aetiology

Following a fall, a 72-year-old man developed leg ulcers of mixed aetiology on his lower limb. These were treated by the district nursing team for 8 weeks.

The patient had a history of both venous and arterial disease. The wound was diagnosed as a leg ulcer of mixed aetiology by the vascular team. His comorbidities were hypertension and dementia.

The district nurses (DNs) cleansed the wound with normal saline. To remove devitalised tissue, a hydrogel dressing that promotes autolysis was used, but with little success. This was covered with Aquacel Extra dressing. Following a vascular clinic appointment, a reduced compression bandage system was applied.

Although wound pain was not a significant problem, due to his dementia, the patient experienced distress and anxiety, resulting in episodes of significant agitation. Because of this and the presence of arterial disease, the district nursing team were reluctant to use a curette or other type of blade, even though they had received training in these procedures.

Treatment

Due to the slow progression of the wound, the DN sought advice

from a TVN, with both attending the patient's home to undertake a comprehensive holistic assessment.

Multiple wounds were present on the lower limb, which comprised approximately 40% necrotic tissue, 30% slough and 30% granulation tissue (*Figure 4*). The slough and necrotic tissue were dry and adherent. The slough was, on occasion, malodorous, which embarrassed the patient. The wounds were producing a low volume of serous exudate. The edges were healthy, but the periwound skin was warm to the touch. The TVN considered that the presence of devitalised tissue and biofilm in the wound was delaying healing.

The TVN recommended that ChloraSolv be used, as it was important that the devitalised tissue be removed quickly and atraumatically, particularly given the risks associated with the patient's arterial status and the extreme distress he had been experiencing at dressing change. The patient and his wife consented to this treatment, as they were keen to promote a good outcome.

Patient outcome

The ChloraSolv was initially applied by the TVN. After the two consecutive applications, it was possible to gently remove approximately 10% of the devitalised

tissue with soft gauze, with minimal discomfort for the patient. After this, ChloraSolv was applied by the DN only. The next application was on day 5, when all the remaining necrotic tissue and most of the slough were easily removed without any pain. The wound bed then comprised 20% slough and 80% granulation tissue.

The DN next applied ChloraSolv on day 10, when the remaining slough was easily and gently removed. The wound bed was then clean, comprising 100% granulation tissue, and the periwound skin was healthy and intact. Full healing was achieved on day 14 (*Figure 5*).

Patient experience

The patient and his wife were also extremely pleased at how quickly and easily the wound bed was debrided. As a result, the patient was no longer agitated or distressed at dressing changes, which were now less frequent. This greatly improved his quality of life.

Health professionals' perspective

The DN was also pleased with how quickly the ChloraSolv removed the devitalised tissue and by how easy it was to apply. The district nursing team as a whole were impressed by this simple but effective method of debridement, particularly given the presence of arterial disease.

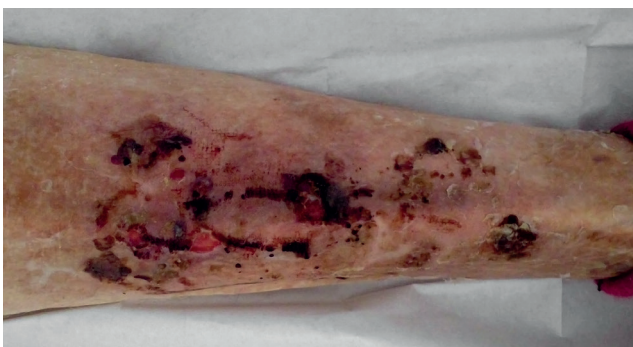

Figure 4. Wound before treatment with ChloraSolv

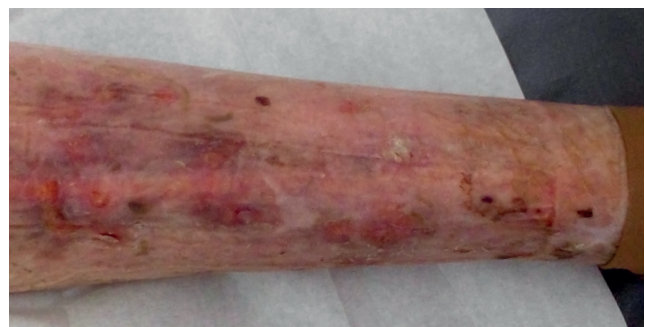

Figure 5. Wound healed 14 days after starting ChloraSolv treatment

Case study 3: leg ulcer, traumatic injury

An 84-year-old man had been receiving treatment from both the community nursing team and the podiatry team for a non-healing wound on his lower limb, located over his Achilles tendon. It was understood that the wound, which had occurred 3 years previously, had resulted from shear and friction caused by poorly fitting footwear.

The patient had diabetes, which at times was not self-managed well due to his poor diet. To help address this, the diabetic specialist team provided him with advice on nutrition and diabetes. His comorbidities were coronary heart disease and hyperthyroidism. It was thought that these and his poor nutrition may have contributed to the delayed wound healing. Holistic assessment of the patient, limb and wound by the district nursing team and the hospital podiatrist identified no significant indicators of arterial disease and neuropathy to his foot.

Wound treatments given in the previous 3 years by the community nursing team comprised wound debridement with a surfactant solution and soft debridement pad, various wound dressings and use of an offloading foot device. Despite this, the wound failed to heal. It became locally infected several times, for which antimicrobial dressings were prescribed. In some instances, the local infection became

systemic, requiring antibiotics; on four occasions, this resulted in hospital admission. Sharp debridement was not attempted because of the risk of damage to the Achilles tendon.

Treatment

As the wound was not progressing, the district nursing team referred the patient to the TVN. Therefore, the TVN and a DN undertook a joint holistic assessment of the patient (*Figure 6*).

The wound, which was shallow, measured 7x4cm. The wound bed was entirely covered with slough and was producing a moderate volume of purulent, thick exudate, which had made autolytic and mechanical debridement challenging. However, there were no clinical signs of local infection, and the periwound skin was intact, with no erythema, although a small amount of maceration was present, which it was feared could cause the wound edges to increase in size. The patient was experiencing moderate wound pain (VAS score 4/10).

The patient reported that the wound was causing him a high level of stress and anxiety, and he was often

reluctant to leave the house for fear of leakage or embarrassment due to the malodour. The episodes of infection had caused him significantly increased pain and discomfort.

As the previous methods of debridement used had never been fully effective, the TVN suggested using ChloraSolv instead. This was discussed with the patient, who consented to the treatment.

Patient outcome

The first application of ChloraSolv was undertaken by the TVN on day 1. The slough instantly started to lift off. After the second application on the same day, 50% of the slough had been removed, with the remainder of the wound bed now covered with granulation tissue. The speed and extent of the debridement surprised the TVN.

ChloraSolv was next applied by the DN at the next dressing change on day 5 (*Figure 7*). Following the second application on this day, the proportion of slough present reduced to 30%. The periwound maceration had also improved. The third and final application was undertaken by the patient's podiatrist during an appointment at the diabetic foot

'The patient found ChloraSolv to be far more comfortable than previous methods of debridement'

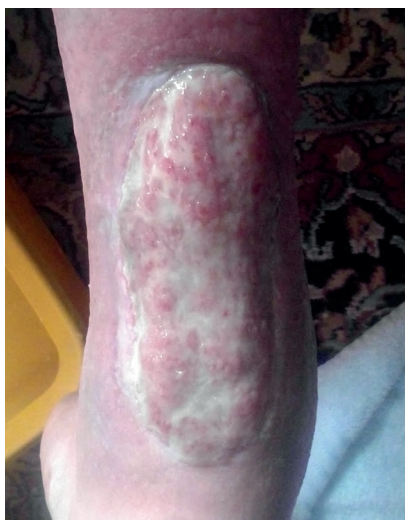

Figure 6. Wound before treatment with ChloraSolv

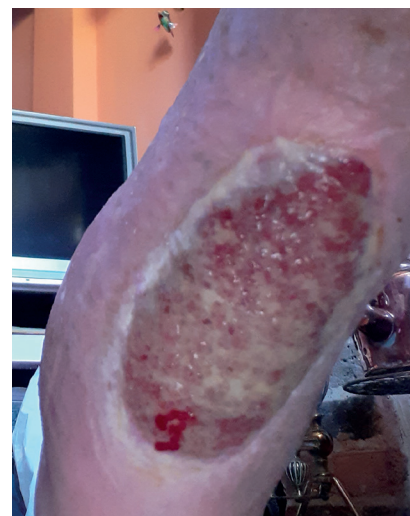

Figure 7. Wound on day 5 after treatment with ChloraSolv

clinic on day 10, when all the sloughy tissue was removed. By this point, the wound was producing a low volume of serous exudate.

For all applications, ChloraSolv was applied to the wound for 2 minutes, in accordance with the manufacturer's instructions, and then washed off with normal saline using a soft gauze pad. After this, a gelling fibre dressing was used to promote autolysis and provide a moist wound environment. The patient continued wearing his offloading footwear throughout.

At the next dressing (day 14), there was still no slough on the wound bed. The wound now measured 5x3cm and was covered with granulation tissue.

Patient experience

The patient was very pleased with the outcome achieved with ChloraSolv. He said that he found this method of debridement far more comfortable than the previous methods he had experienced. Furthermore, he no longer experienced any wound pain after the slough had been completely removed on day 10. He was very satisfied with the ability of ChloraSolv to cleanse and debride this long-standing wound and reassured that it was finally improving, which in turn reduced his anxiety. He was confident about going out, as there was no leakage or malodour. As such, his quality of life improved.

Health professionals' experience

The TVN, DN and podiatry team were all pleased with their experience of using ChloraSolv. The TVN was surprised by how quickly the gel removed so much slough at the start of this treatment, making it a valuable debridement method. The podiatrist said it was very easy to apply and had been so effective that there was no need to even consider sharp debridement. The district nursing team were impressed by the fast action, simplicity, ease of use and safety profile of ChloraSolv and that no specialist training was required. A key advantage was that it could be used by a range of staff within the team.

Q&A: Joy Tickle



What debridement methods did you use in the past and why?

We use a variety of methods to remove devitalised tissue from the wound bed and periwound skin: surfactants or wound dressings to promote autolysis; mechanical methods with soft pads; sharp debridement using instruments such as scalpels, scissors and curettes. The choice of debridement method depends on patient preference, the wound aetiology and location, and the health professional's knowledge and skills.

How effective do you think this was, particularly in removing wound biofilm?

These debridement techniques did not always effectively remove slough and devitalised tissue or reduce biofilm.

How does ChloraSolv compare with the debridement methods you used in the past?

Compared with these other methods of debridement, ChloraSolv is extremely effective in a short space of time. It has debrided slough and necrotic tissue that other

debridement methods have failed to remove. By helping to achieve a clean wound bed, it has reduced the need for antimicrobial dressings. It can also be used on patients who cannot tolerate other debridement methods due to pain and discomfort.

How would you describe the patient's experience with ChloraSolv?

As use of ChloraSolv promotes a clean wound and reduces the signs and symptoms associated with non-healing, patients have reported increased comfort and improved quality of life following its application. For example, one patient told us that, due to the reduction in wound malodour and the high exudate volume he experienced after its use, he was able to welcome visitors to his home and go out to socialise, which he had not been confident enough to do for several months.

Will you continue using ChloraSolv in the future? And, if so, why?

Yes, we will aim to do so. Its rapid action is particularly beneficial for patients who are at high risk of

delayed healing and infection. Also, as it is simple to use and does not require specialist training; all staff can use it.



What type of patient or wound would you use ChloraSolv on?

We intend to use it, when indicated, on patients whose wounds have not responded to standard of care; on wounds in which devitalised tissue recurs rapidly after debridement; on patients whose comorbidities place them at increased risk of non-healing and infection; and on patients who cannot tolerate mechanical debridement or are unsuitable for it.

Which health professionals would benefit most from ChloraSolv?

Most health professionals can use ChloraSolv. Having said that, until the product becomes more established, I expect generalists would want to consult with a specialist nurse before using it.

Case studies 4–6: diabetic foot ulcers



Kimberley Wilde, Advanced Podiatrist, Manchester University NHS Foundation Trust, UK

Case study 4: diabetic foot ulcer

A 55-year-old woman with type 2 diabetes mellitus and venous insufficiency had a painful foot ulcer located on the posterior aspect of the heel. The wound, which had been present for 12 months, was caused by pressure, but the patient's poorly controlled diabetes had impaired healing. The patient was under the care of a vascular team, who assessed that her arterial supply was sufficient. She was awaiting radiofrequency ablation surgery for the venous disease.

Following presentation at the podiatry clinic, the wound was assessed as being locally infected, with clinical signs of heat, redness and pain—the patient's self-reported visual analogue (VAS) score was 8/10, where 10 is the worst pain possible. The wound bed comprised 20% necrotic tissue, 30% granulation tissue and 50% adherent slough (*Figure 1*). The wound management regimen comprised:

- Soaking with an irrigation solution

containing polyhexanide (PHMB) and betaine for 5–10 minutes

- Application of an alginate gel containing antimicrobial enzymes
- Application of an absorbent foam dressing
- Offloading with a soft heel cast.

The patient could only tolerate minimal debridement with a scalpel, finding the pressure on the wound uncomfortable. Mechanical debridement had not been attempted.

Treatment

The patient consented to the use of ChloraSolv as she was keen to see if it would help improve the wound without causing her pain.

Patient outcome

The podiatrist debrided the wound with ChloraSolv. After the first application, she was able to gently remove approximately 20% of the slough with gauze. The patient reported that this was pain-free. The podiatrist then undertook the

second application, after which she was able to gently remove the remaining slough and necrotic tissue with a blade, as it was now softer and not adhering to the wound bed. The wound bed comprised 100% granulation tissue (*Figure 2*).

The wound continued to improve, reducing from 3.5x3.0cm on day 1 to 3.0x2.5cm 6 weeks later. No further applications of ChloraSolv were required during this time, as the wound bed stayed clean throughout.

Patient experience

The patient was very satisfied with ChloraSolv, as its use resulted in a cleaner wound bed without causing her any distress.

Health professionals' experience

Given that this patient had experienced high levels of wound-related pain and was unable to tolerate sharp debridement, the podiatrist considered that ChloraSolv was an ideal way of debriding the wound bed without causing any discomfort or distress.

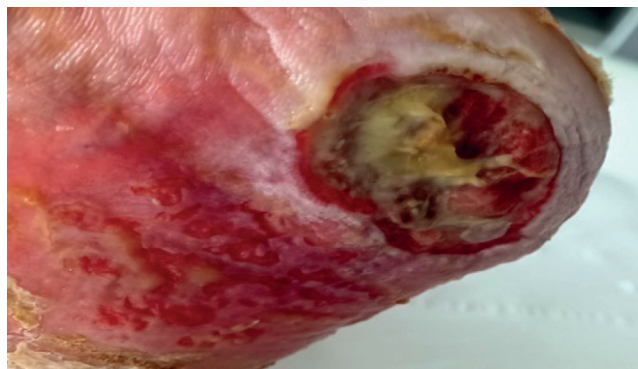


Figure 1. Wound before first application of ChloraSolv

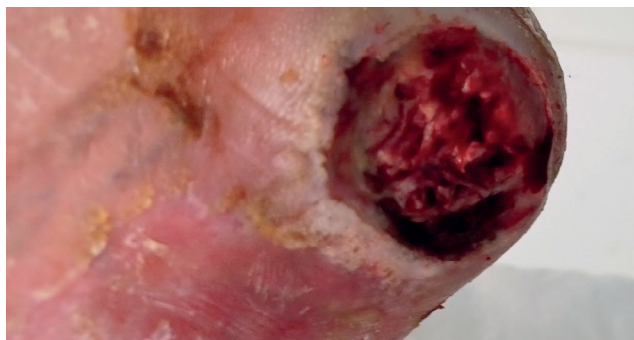


Figure 2. Wound after the second application of ChloraSolv

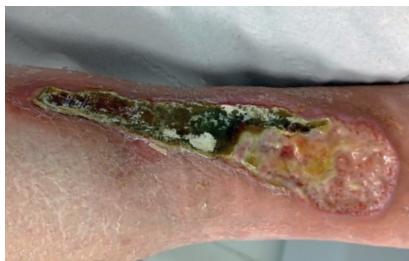

Figure 3. Wound before first application of ChloraSolv

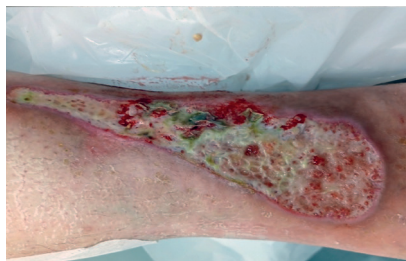

Figure 4. Wound after application of ChloraSolv on day 1

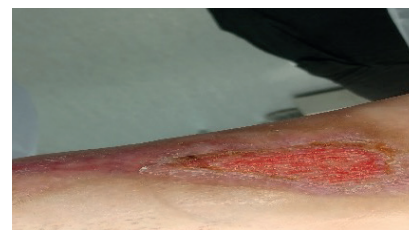

Figure 5. Wound 6 weeks after the first application of ChloraSolv, with a clean wound bed

Case study 5: diabetic foot ulcer, blister

A 30-year-old man with type 1 diabetes mellitus, peripheral neuropathy and history of partial-foot amputation presented at the podiatry clinic with a large blister on the anterior aspect of his right lower leg. The patient had recently been discharged from hospital following an acute kidney injury. He had some oedema in both lower legs.

The patient had noticed the blister after kneeling down to do some housework. On the next day, the blister burst, and he immediately presented at the treatment room clinic as an emergency.

The clinic nurses applied a dressing to the blister, but it deteriorated over the next 2 weeks, and the wound bed became sloughy. The patient was unable to work because of the wound.

Following assessment at his presentation in the podiatry clinic, the podiatrist soaked the wound with an irrigation solution containing PHMB and betaine for 5–10 minutes and then dressed it with a non-adherent wound contact layer and an absorbent secondary foam dressing. However, after being deroofed, the blister developed hard adherent slough that covered approximately 90% of the wound bed. The podiatrist changed the treatment regimen to a highly viscous gel containing PHMB and betaine and an absorbent pad.

Over the next 4 weeks, the wound started to improve, and, with a combination of autolytic and sharp debridement, some of the slough lifted. However, a large adherent plaque of dry slough still covered 60% of the wound bed (*Figure 3*).

The wound was impairing the patient's quality of life. The exudate volume was high, and, at times, his clothes were soiled because of strikethrough. His regular visits to podiatry, the treatment room nurse and his diabetologist were a financial burden for him, as he was not working and had to take taxis.

Treatment

As the plaque of slough was difficult to debride with a scalpel, the podiatrist decided to try ChloraSolv instead. Following application and removal of the gel, the wound was covered with a wound contact layer and an absorbent pad.

Patient outcome

Initially, one syringe was applied for 2 minutes and then removed, after which 80% of the plaque was gently lifted off with a blade and curette. A second syringe was applied and removed at the same appointment to help achieve a cleaner wound bed. *Figure 4* shows how the two consecutive applications of ChloraSolv supported the debridement and led to a healthier wound bed, which was now covered with 40% granulation

tissue and 60% loose slough, but no plaque. At the next dressing change, the loose slough was removed with the irrigation solution and minor sharp debridement, as required. The wound bed remained clean. *Figure 5* shows the wound 6 weeks after the use of ChloraSolv: it was completely covered with granulation tissue and progressing towards healing.

Patient experience

The patient was eager for the wound to heal so that he could improve his quality of life and pursue new work opportunities. He was amazed at how quickly the ChloraSolv worked and stated how pleased he was that the wound was looking so good.

Health professionals' experience

The podiatrist found ChloraSolv to be effective and simple to use. Following a single application, it was extremely easy to remove the previously dry, adherent slough.

'The patient was amazed at how quickly ChloraSolv worked and was pleased with the result'

Case study 6: diabetic foot ulcer

A 73-year-old man with type 2 diabetes mellitus, peripheral neuropathy, peripheral arterial disease and congestive heart failure presented at a podiatry clinic with two wounds on the top of his right foot. He explained that, 2 days before his presentation, he had placed a hot water bottle in his bed, as his feet were cold. Due to the peripheral neuropathy in his feet, he had not detected that this was burning his foot.

At presentation, the largest of the two wounds measured 7.5x5.2cm, with the wound bed comprising 75% adherent slough and 25% granulation tissue. There were clinical signs of infection (heat, swelling and redness) extending past 2cm from the wound edges, and the exudate volume was high. The infection was assessed as cellulitis, for which a 1-week course of oral antibiotics (flucloxacillin 1g, four times a day) was prescribed.

‘Only one treatment with ChloraSolv was needed to facilitate removal of a plaque of dry, adherent slough’

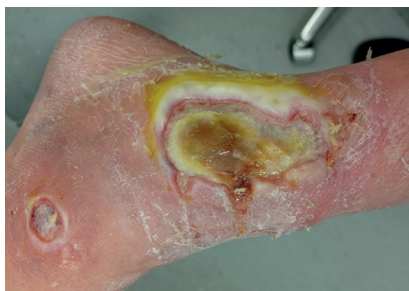

Figure 6. Wound before the first application of ChloraSolv

The wound was impairing the patient's quality of life. He was unable to shower because of it. In addition, the antibiotics elevated his blood-sugar levels, resulting in him having to see his diabetologist more often. He also required more frequent dressing changes in the podiatry clinic.

Standard of care for the prevention and management of diabetic foot ulcers requires implementation of at least one of the following: offloading, control of infection, control of ischaemia, debridement and use of wound dressing(s).¹ Therefore, the treatment plan for this wound comprised:

- A 10-minute soak with an irrigation solution containing PHMB and betaine, to promote wound bed preparation
- Application of an antimicrobial enzyme-containing alginate gel covered with an absorbent pad.

The podiatry team assessed the wound at weekly intervals when the dressings were changed. The podiatrist was only able to perform minimal sharp debridement at these visits, as the slough was very adherent.

Treatment

The treatment plan was reviewed 4 weeks after the initial presentation. The infection had been managed successfully, but the wound bed still comprised 100% slough (Figure 6).

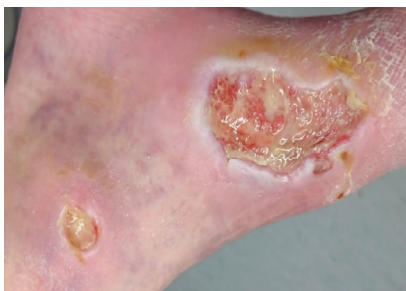

Figure 7. Wound after application of the second syringe on day 1

‘8 weeks after the application of ChloraSolv, the wound bed remains clean and is healing well’

The slough was so adherent that it could not be lifted off with a blade. The wound measured 6x3cm.

Therefore, the podiatrist decided to use ChloraSolv to aid the debridement process, cleanse the wound bed and move the wound out of the inflammatory phase of healing. The dressing regimen stayed the same, although the irrigation solution was no longer required.

The patient was keen to try out a treatment that could help debride the wound.

Patient outcome

After the first application on day 1, the slough became softer, making it possible to lift off approximately 50% with a blade (Figure 7). After the second application (day 7), almost all the remaining slough was removed with a curette and gauze in places, leaving 90% granulation tissue (Figure 8). It was not considered necessary to use ChloraSolv again, and the remaining slough was

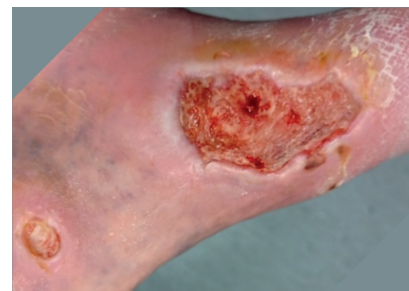

Figure 8. Wound after application of the second syringe on day 7

debrided with gauze. By this time, the exudate volume had reduced from moderate to low. At the time of writing (week 8), the wound bed remained clean and was progressing towards healing.

Patient experience

The patient did not experience any discomfort during the application of ChloraSolv. He commented that the wound started to look much better following the use of ChloraSolv and felt relieved and happy that it was starting to heal. Because of his diabetes, he had been very worried about his burn injury. He was aware of how this could affect his feet

and feared amputation. He felt more reassured once he could see the improvement.

Health professionals' experience

The podiatrist found ChloraSolv extremely easy to use and was impressed by how quickly and effectively it debrided the wound bed. She believed that this product had potential to greatly improve the outcomes of hard-to-heal wounds.

Reference

1. National Institute for Health and Care Excellence. Diabetic foot problems: prevention and management. 2019. www.nice.org.uk/guidance/ng19 (accessed 20 April 2022)

Q&A: Kimberley Wilde



What debridement method did you use in the past and why?

I have always used sharp debridement, predominately because I was trained on this at university. I have been applying this skill for the past 22 years. I am always open to innovation and products that might aid debridement. Not every patient can tolerate sharp debridement and it is not always effective for every wound—I have also used debridement pads effectively on some patients.

How effective do you think this was, particularly in removing wound biofilm?

Sharp debridement is an effective way of removing and disrupting biofilm growth and promoting faster debridement. However, it can be challenging to remove very adherent slough or debride selectively in cavities and undermining.

How does ChloraSolv compare with the debridement methods you have used in the past?

In my experience, ChloraSolv enables effective debridement and cleans the wound bed. It exceeds many of the debridement methods I have used in the past, such as autolytic debridement treatments and debridement pads. I feel it

complements sharp debridement and can be used as an alternative to it in wounds with a thin layer of slough.

How would you describe the patient's experience with ChloraSolv?

Each patient I have used ChloraSolv on has had a positive experience of the gel. There have been no adverse effects, and every wound has improved afterwards. I have used it on a patient with a sloughy wound who found sharp debridement painful. The patient found ChloraSolv to be pain-free. The gel enables me to debride the wound bed without causing discomfort or distress to my patients.

Will you continue using ChloraSolv in the future? And if so, why?

Yes, as I have had excellent clinical results with it. ChloraSolv enables the health professional to clean the wound bed quickly, so that the wound can move into the proliferation stage of healing. It is very easy to use and works within 2 minutes. I work in a busy NHS clinic and, due to the time pressures, I want a product that works quickly.

What type of patient or wound would you use ChloraSolv on?

Any wound that is painful to sharp debride and/or with adherent slough.

It would also be

beneficial for interdigital wounds and those with a sinus, as

it can be difficult to sharp debride these areas and there

is an increased risk of damaging healthy tissue.



Which health professionals would benefit most from ChloraSolv?

I think that all health professionals who treat wounds would benefit from using ChloraSolv, both in community and acute settings. It is an excellent product for health professionals who are treating sloughy wounds. In my experience, the gel is effective, easy to use and works quickly. In my opinion, health professional who do not have the training to sharp debride will be able to debride the wound bed effectively with ChloraSolv and a curette. The long-term benefits should be better wound outcomes, which will improve patients' quality of life, save staff time and reduce the cost of wound care.

Conclusion



ChloraSolv is an innovative debridement product, indicated for use on diabetic foot ulcers and leg ulcers, which softens devitalised tissue and rapidly kills biofilm, so that these can be simply and easily removed. The speed and ease with which it can achieve this, as demonstrated in the case studies featured in this supplement, make it an excellent alternative to sharp and mechanical debridement. It can also serve as a helpful complement to a blade, as its gel-like consistency can penetrate hard-to-reach locations, such as cavities and areas between digits, softening devitalised tissue that can then be removed with a blade, blunt instrument, pad or wipe.

As such, ChloraSolv enables fast and efficient removal of devitalised tissue and biofilm. Within minutes of its application, the softened slough and necrotic tissue can be rinsed and wiped away, or gently scraped if needed, to achieve a cleaner wound bed. Some of the case studies describe how this resulted in the removal of virtually all devitalised tissue. In some cases, there was no need for further debridement, or, if devitalised tissue recurred, full wound bed preparation was quickly achieved in the next one or two follow-up visits. All of the wounds subsequently healed or improved. All were hard to heal before the initial application of ChloraSolv.

Not only does ChloraSolv promote removal of devitalised tissue and biofilm, facilitating wound bed preparation, but it does this without causing trauma or bleeding, as the softened tissue can be easily rinsed or rubbed off. Most of the patients in the case studies were previously unable to tolerate debridement because of the pain and discomfort it caused them, which greatly impaired healing. For many, this had a terrible effect on their quality of life, with the fear of leakage, malodour and the ongoing wound pain impeding their day-to-day lives. The gentle action of ChloraSolv made a debridement acceptable and tolerable to them.

ChloraSolv is selective, posing no risk to vital tissue when used per instructions for use (IFU). Its excellent safety profile and ease of use, whereby minimal training is required to apply it, means that the gel can be used by any health professional involved in wound care, regardless of their skills and experience. Therefore, it can be easily incorporated into all wound management pathways, such as the Wound Hygiene protocol of care. By enabling fast and efficient debridement that can be safely undertaken by all health professionals, it is likely to increase implementation of these pathways. This should help standardise care and improve patient outcomes. Other dividends include potential savings in nursing time and resources, as easier, faster and more

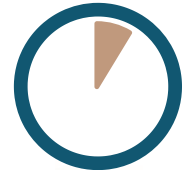efficient wound bed preparation that results in a clean wound bed is likely to reduce the risk of prolonged inflammation and increased bioburden and, therefore, the need for antimicrobials, advanced dressings and more frequent nurse visits.

It is sometimes said that wound care is in crisis, with the ageing population resulting in an ever-increasing incidence of wounds on the lower limb, incurring a high health-economic burden. Addressing this requires widespread implementation of standard of care, including treatment of the underlying wound aetiology, thorough wound bed preparation, implementation of antibiofilm strategies and the promotion of a wound environment that is conducive towards healing. Debridement is a key aspect of wound bed preparation and antibiofilm care, but the clinical challenges associated with it, such as fear of damaging or removing vital tissue when using a blade or causing harm, as well as the pain it can cause patients, can hinder its full implementation. Clearly, there is a need for a debridement product that can ensure fast and efficient selective debridement of devitalised tissue and biofilm. Due to its unique mode of action, which creates a high alkaline and oxidative environment that softens tissue and has an antimicrobial and antibiofilm effect, ChloraSolv can do just this.

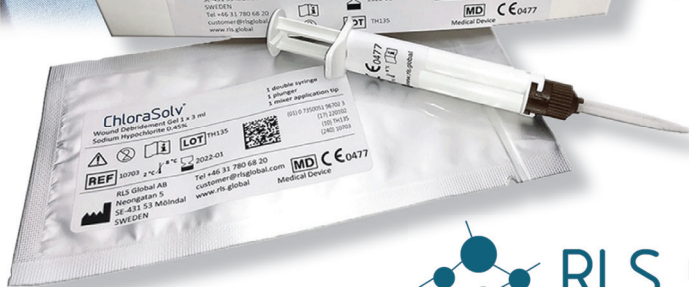



Experience the difference for yourself, in less than 5 minutes

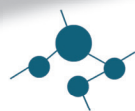

<5 minutes



ChloraSolv[®]

Convenient, effective & gentle debridement of lower leg and diabetic foot ulcers



RLS GLOBAL

Gentle Methods



convatec

— forever caring —

1. Eliasson, B., Fagerdahl, A.-M., Jönsson, A., Apelqvist, J. Debriding effect of amino acid-buffered hypochlorite on hard-to-heal wounds covered by devitalised tissue: pilot study. Journal of Wound Care (June 2021) 30:6. 2. Instructions For Use. 3. Data on file, RP-00008 Biological Evaluation. 4. Data on file, RP-00087 ChloraSolv Claims Verification. 5. Olausson S. Ahlenius M. Fast and complete eradication of biofilm by wound debridement gel. EWMA 2021.

©2022 ConvaTec. TM/_® indicate trademarks of the Convatec group of companies other than ChloraSolv[®] and the RLS logo which are trademarks of RLS Global AB. ChloraSolv[®] is manufactured by RLS Global AB and distributed by Convatec. AP-55017-GBL-ENG

