

**Case Series:** The use  
of AQUACEL™ Ag Extra™  
dressing on Chronic and  
Acute Wounds



# Executive Summary

ConvaTec, the company that brings you the anti-microbial dressing, AQUACEL™ Ag, has taken its Hydrofiber™ Technology to the next level with the introduction of AQUACEL™ Ag Extra™ Dressing. AQUACEL™ Ag Extra™ Dressing consists of two layers of Hydrofiber™ Technology stichbonded together to provide 50% more absorbency and 9 times greater strength vs. AQUACEL™ Ag dressing.<sup>1\*</sup>

The purpose of the following case series is to add to the robust compilation of evidence supporting the AQUACEL™ family of dressings. This case series puts AQUACEL™ Ag Extra™ dressing into the hands of two clinicians to gain *in vivo* experience and show how the added strength and absorbency translates into clinical benefits.

The evaluation was continued for four weeks or until the dressing was no longer clinically indicated. If the wound progress warranted longer use, the dressing was continued at the discretion of the clinician.

## Kevin Woo PhD, RN, FAPWCA



Dr. Kevin Woo is an internationally renowned wound care clinician who also maintains an academic focus as an Assistant Professor (Tenure track), Faculty of Health Sciences, School of Nursing, Queen's University. He is also the current Web Editor for *Advances in Skin and Wound Care*, <http://journals.lww.com/aswcjournal>.

Dr. Woo's clinical focus is as a Wound Care Consultant at the West Park Health Center in Toronto, Canada. West Park Health Center is an acute care facility of over 200 beds including an associated Complex Continuing Care Center, a Long Term Care unit and a Rehabilitation and Community Living Unit. Dr. Woo is consulted most commonly on acute and complex chronic wound patients with underlying medical conditions such as Diabetic associated amputations, ventilator dependent patients, and venous insufficiency.

## Kathryn Braun, RN, WRN, IIWCC



Kathryn Braun, RN, WRN, IIWCC 2001, graduated from Brandon General Hospital School of Nursing in Manitoba in 1981. She has worked in a variety of settings including medical, surgical, ostomy, post-partum, emergency and community care. She took the IIWCC (International Interdisciplinary Wound Care Course) through the University of Toronto in 2001 after which she initiated a formal wound care program for her employer, the Regina Qu'Appelle Health Region. This led to her taking on the role of Wound Care Coordinator on a fulltime basis in 2002. She has a passion for wound care and is currently working as the Wound Care Consultant for the RQHR Treatment Centre where she is consulted on hard-to-heal wounds and does ongoing wound education for the nursing staff there. She is also employed by ConvaTec on a contract basis to deliver the HEAL wound care education program in Saskatchewan and Manitoba.

Authors are paid consultants of ConvaTec Inc.

1) Buggedo A, Bowler F, Bishop SM, 2012. Assessment of the *in vitro* physical properties of AQUACEL™ Ag Extra™ and AQUACEL™ Ag dressings. *Technical Assessment*. WHRI3602 TA235. 2012, Data on File, ConvaTec Inc.

\* as demonstrated *in vitro*

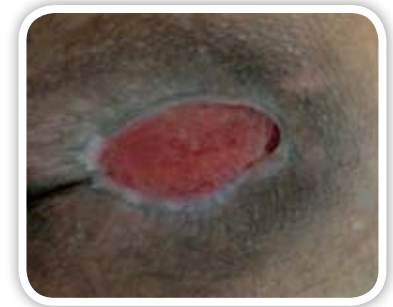# Case Study 1: Pressure Ulcer

Author: Kevin Woo PhD, RN, FAPWCA

## Introduction:

WP-T is a 23 year old male admitted to ICU with acute vasculitis and kidney failure. Prior to this admission there were no comorbidities that would contribute to the development of this wound, other than a recent weight loss associated with this diagnosis. While in ICU he remained mobile. A support surface (air overlay) was used for pressure redistribution. He had a hemoglobin of 110 and his albumin was 30 indicating poor nutrition or malnutritional status.

A full thickness sacral pressure ulcer developed. At study baseline visit, this wound measured greater than 3cm in length, approximately 2.1-2.5cm in width and less than 0.5cm deep. The wound bed presented with 100% granulation tissue. Although there was no clinical sign indicating deep wound infection, heavy exudate, odour, and light green drainage suggested critical colonization that would benefit from topical management with an antimicrobial agent. Protocol of care at study baseline visit included cleansing the wound with saline and application of a foam dressing as the primary wound contact layer. Dressings were changed three times per week due to heavy exudate that had created periwound skin damage as evident by skin maceration.



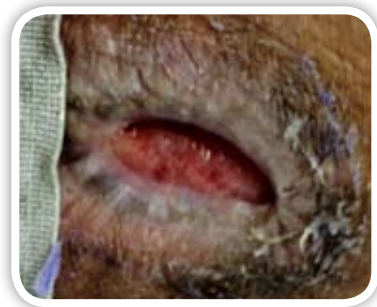
6/22/2012

## Methodology:

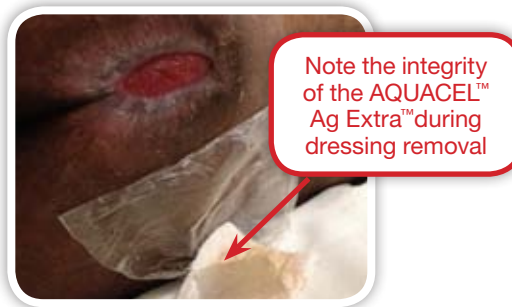On 6/22/2012, a new dressing evaluation was initiated. The wound was cleansed using saline. AQUACEL™ Ag Extra™, a new Hydrofiber™ with silver dressing, was applied as the primary dressing. A Ete™ dressing secured with a Tegaderm™ dressing was used as the cover dressing during this evaluation. Dressings continued to be changed three times per week.

## Results:

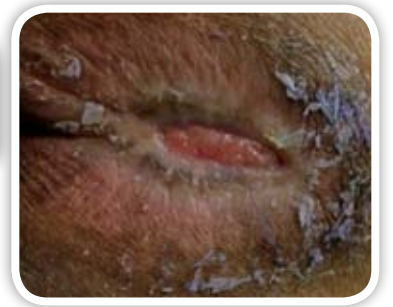
At the seven day evaluation, the wound showed significant contraction and size reduction, as well as decreased maceration due to the lateral wicking of exudate into the AQUACEL™ Ag Extra™ dressings.



6/29/2012



7/06/2012



7/13/2012

At the end of the 4-week evaluation, the wound was less than 50% of baseline size, and the wound bed was 75% granular and 25% epithelial tissue. The periwound skin remained intact with no further maceration.

## Discussion:

The AQUACEL™ Ag Extra™ dressing was easy to tailor and conform to the wound bed. It provided excellent exudate absorption, exudate retention, and remained intact during dressing removal without leaving residue on the wound bed. Both the condition of the wound and periwound skin improved as described above. The patient rated the comfort during dressing change and wearing of the new dressing as excellent.

# Case Study 2: Diabetic Foot Ulcer

Author: Kevin Woo PhD, RN, FAPWCA

## Introduction:

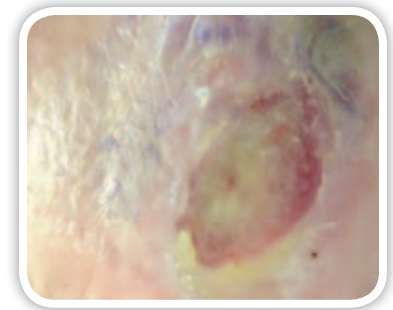
WP-H is a 66 year old male with a history of Hypertension and type 2 Diabetes with stable glycemic control and peripheral vascular disease. He presented with a diabetic foot ulcer on the right heel that was less than six weeks duration. The wound measured 3.5cm in length, 2.4cm in width and less than 0.5cm in depth. At study baseline visit, the wound bed was 75% covered in slough and 25% pale granulation tissue. The peri-wound skin was macerated and wet. Moderate amounts of malodorous and thick tenacious exudate was present indicating that the wound was critically colonized.

The previous protocol of care included cleansing the wound daily with normal saline, application of an iodine-based paste dressing, and covering with a non-adherent gauze and tape.

## Methodology:

On 7/27/2012, a new dressing evaluation was initiated. The wound was cleansed using saline. AQUACEL™ Ag Extra™, a new Hydrofiber™ with silver dressing, was applied as the primary dressing. The secondary dressing included application of a non-adherent gauze cover dressing secured with self adhesive fabric tape. Daily dressing changes were maintained initially for 1 week then reduced to three times a week.

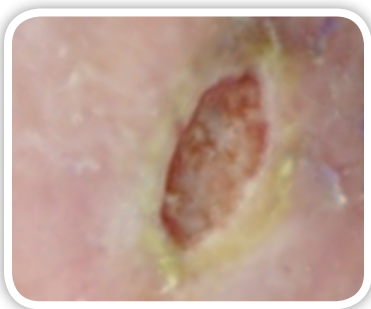
In accordance with best practice, the hyperkeratotic area in the periwound skin was debrided with a scalpel on a weekly basis.



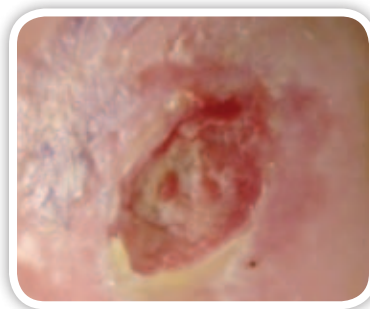
7/27/2012

## Results:

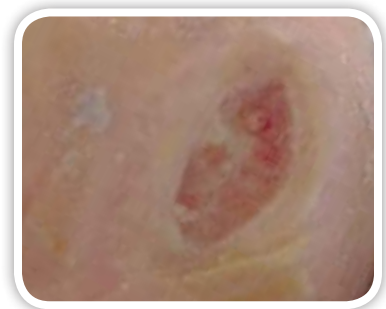
At the end of the four week evaluation, the wound had decreased in size significantly (1.7cm in length, 0.8 cm in width and 0.2cm in depth). The wound bed now presented with 25% fibrin and 75% granulation tissue, which appeared to be a healthier red color. Wound drainage was described as clear and the quantity had noticeably reduced.



8/03/2012



8/10/2012



8/17/2012

## Discussion:

This wound showed significant debridement with the new dressing routine. The granulation bed improved and a favorable reduction in wound size was noted. The patient rated the comfort of the dressing as excellent.

# Case Study 3: Venous Stasis Ulcers

Author: Kevin Woo PhD, RN, FAPWCA

## Introduction:

WP-C is a 62 year old female who presented with bilateral venous stasis ulcers that were present less than 6 weeks. She has a history of osteoarthritis awaiting bilateral knee replacement. The date for her surgery depended on when the ulcers could be closed to prevent post-op complications. She did have a history of venous insufficiency with ABPI of 0.79 and was advised to wear compression stockings.

At study baseline, both legs had very mild pitting edema (+1). Her right leg presented with a venous stasis ulcer that measured 5cm in length, 3cm in width and less than 0.2cm in depth. The wound bed presented as beefy red and friable. The peri-wound skin was macerated and wet. Her left leg presented with two venous stasis ulcers; one measured 2.7cm in length, 2.4cm in width and less than 0.2cm in depth and the other measured 2.3cm in length, 1.4cm in width and less than 0.2cm in depth. Both ulcers also had granular beds and heavy exudate with a pungent smell and light green discoloration.

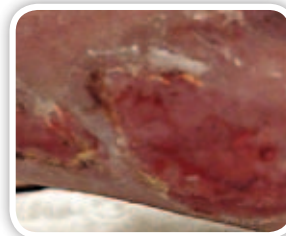
Current wound management included wound cleansing with normal saline, application of a silver foam dressing followed by a Compression wrap twice per week.

## Methodology:

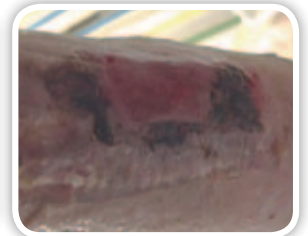
On 6/22/2012, a new dressing evaluation was initiated. The wounds were cleansed using saline and a Hydrofiber™ with silver AQUACEL™ Ag Extra™ dressing was applied as the primary dressing. The same method of compression was maintained as previously and dressing changes were continued twice weekly for the first week then reduced to weekly.

## Results:

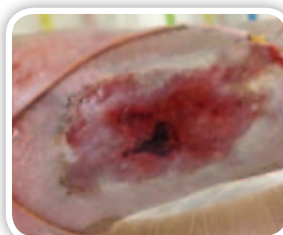
All three ulcers responded to the new protocol of care favorably. A reduction in wound surface area was measurable. At the end of the study, all wound beds exhibited significant amount of epithelialization. There was a significant improvement in the peri-wound skin and signs related to critical colonization as evidence by reduction in drainage over time.



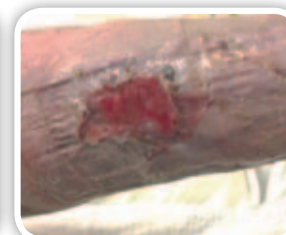Left Leg – 6/22/2012



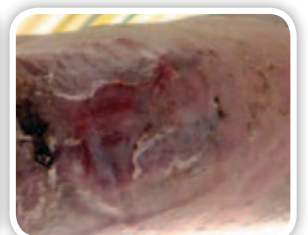Left Leg – 7/20/2012



Right Leg – 6/22/2012



Right Leg – 7/06/2012



Right Leg – 7/20/2012

## Discussion:

Of note with this patient was the resolution of pressure under compression as demonstrated (right leg photos from 6/22 & 7/6) in the first week of therapy. Using a dressing that conforms to the wound bed and turns into a soft gel mass that can be removed intact indicates that there are no sources of pressure to the wound and periwound skin as seen with use of a foam dressing. The study dressing was able to absorb and retain heavy amounts of exudate and preserve fragile periwound skin. The patient rated the comfort during application and while wearing the new dressing as excellent. Because of the thickness and strong tensile strength of the dressing, there was no need to use a secondary dressing under the compression bandages.

# Case Study 4: Scapular Excision

Author: Kevin Woo PhD, RN, FAPWCA

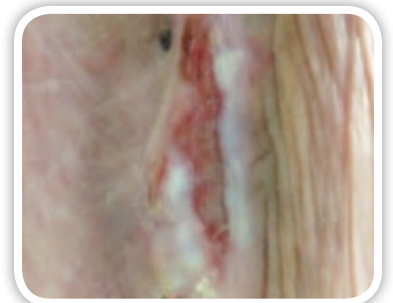
## Introduction:

WP-M is a 73 year old male who in July 2012 had a wide excision of a scapular sarcoma, stage T2b (which indicated the tumor was more than 5cm across and was deep into the body tissues), subsequently developed an infected surgical site wound. At baseline study visit, the wound measured 4.5cm in length, 2.1-2.5cm in width, and 1.6-2cm in depth. The wound bed presented with 25% slough and 75% pale granular tissue. The peri-wound skin was macerated and wet. Moderate amounts of greenish exudate was present.

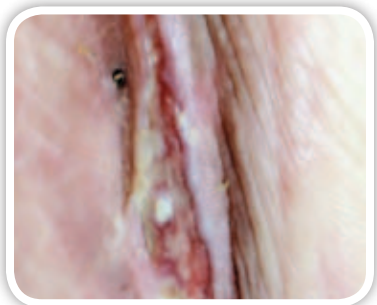Current wound management included cleansing with normal saline, application of a silver alginate dressing followed by a low adherent dressing secured with a film dressing. Dressings were changed four times per week.

## Methodology:

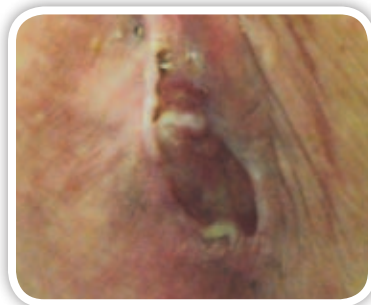
On 7/20/2012, a new dressing evaluation was initiated. The wound was cleansed using saline. AQUACEL™ Ag Extra™, a new Hydrofiber™ with silver dressing, was applied as the primary dressing. The cover dressing protocol did not change during this evaluation. Dressings continued to be changed four times per week.



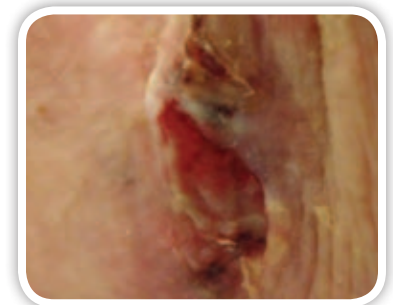
7/20/2012



7/27/2012



8/10/2012



8/17/2012

## Results:

At the seven day evaluation visit, the wound showed significant contraction and size reduction, as well as decreased maceration due to the lateral wicking of exudate into the AQUACEL™ Ag Extra™ dressing. Although decreased, at the end of the 4-week evaluation, moderate amounts of exudate continued. Therefore, the clinical decision was made to continue with the new dressing routine. Dressing changes were reduced to two times per week. At the final evaluation, the wound bed progressed to 75% granulation and 25% epithelial tissue.

## Discussion:

The AQUACEL™ Ag Extra™ dressing was easy to tailor and conform to the wound bed. It provided excellent exudate absorption and exudate retention. It remained intact during dressing removal without leaving residue on the wound bed. The patient rated the overall comfort of the new dressing as excellent.

# Case Study 5: Pressure Ulcer

Author: Kevin Woo PhD, RN, FAPWCA

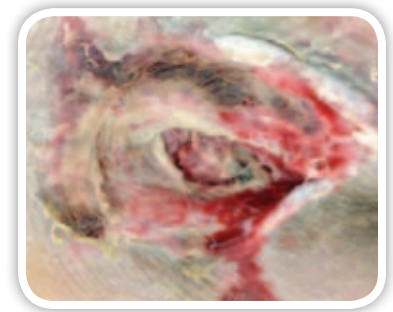
## Introduction:

WPMO is a 59 year old quadriplegic male who developed a full thickness sacral pressure ulcer. He has a history of diarrhea, hypertension, and chronic obstructive pulmonary disease. At study baseline visit, the wound was 6-12 weeks duration, and measured 4.5cm in length, 2.8cm in width and 2.7cm in depth. The wound bed was covered with 25% necrotic tissue, 25% slough and 50% granulation tissue that was friable. The wound was probed to bone suggesting osteomyelitis. The peri-wound skin was macerated and wet. Heavy, foul smelling and rusty colored exudate was present.

Current wound management included cleansing with normal saline, application of a silver alginate dressing, followed by a low adherent dressing secured with a film dressing. Dressings were changed three times per week. IV antibiotics were initiated to treat osteomyelitis.

## Methodology:

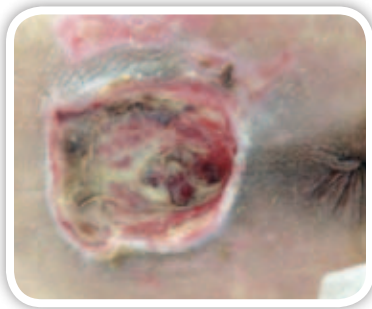
On 7/27/2012, a new dressing evaluation was initiated. The wound was cleansed using saline. AQUACEL™ Ag Extra™, a new Hydrofiber™ with silver dressing, was applied as the primary dressing. The cover dressing protocol did not change during this evaluation. Dressings continued to be changed three times per week.



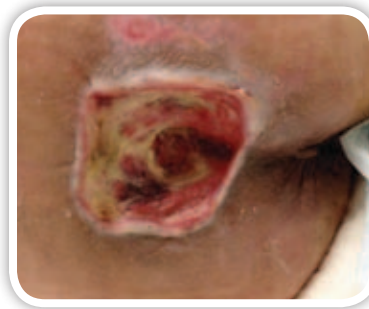
7/27/2012

## Results:

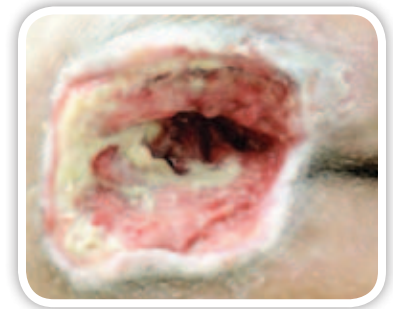
At week four, the wound had decreased in size to 4cm in length, and 2.3cm in depth. The width remained unchanged. All necrotic tissue resolved and the wound bed now presented with 25% slough and 75% healthy granulation tissue. The wound continued to be highly exudative but the drainage was no longer malodorous.



8/03/2012



8/10/2012



8/17/2012

## Discussion:

The dressing helped to contain heavy exudate, and provided an excellent antimicrobial barrier. Clinically, the dressing worked in synergy with IV antibiotic therapy, treating the infection from both internal and external means.

# Case Study 6: Pressure Ulcer

Author: Kevin Woo PhD, RN, FAPWCA

## Introduction:

WPF is a 66 year old male with advanced dementia, hypertension, Coronary artery disease, hypothyroidism, and stroke (10 years ago). He developed a stage 2 pressure ulcer 3 months ago which progressed to a stage 4 pressure ulcer upon return from acute care hospital where he was treated for respiratory failure. At the time of study admission he was totally bed bound, incontinent of bowel and bladder, and suffered from recent weight loss of 10 lbs indicating poor nutrition status. Due to high risk of silent aspiration, the head of his bed was required to be elevated. To prevent sliding and shearing problem, a gel mattress was put in place.

A full-thickness pressure ulcer presented over the lower portion of the sacrum. The duration of this pressure ulcer was longer than 12 weeks. At study baseline visit, the wound measured 3cm in length, 2.5cm in width and 2cm in depth. An undermining of 4cm extended at the two to four o'clock position. The wound base presented with 25% of slough and 75% dusky unhealthy granulation tissue that bled easily with minor manipulation. The periwound skin was macerated & wet. Heavy exudate with brown discoloration and odor suggested clinical infection that would benefit from topical management with an antimicrobial agent.

The previous protocol of care for this wound included cleansing with saline followed by application of a silver polyester dressing as the wound contact layer, then covered with a low adherent dressing secured with a film dressing. Dressings were changed three times per week.

## Methodology:

On 6/22/2012, a new dressing evaluation was initiated. The wound was cleansed using saline. AQUACEL™ Ag Extra™, a new Hydrofiber™ with silver dressing, was applied as the primary dressing. A rayon silk dressing secured with a transparent dressing was utilized as the cover dressing. Dressings continued to be changed three times per week.

## Results:

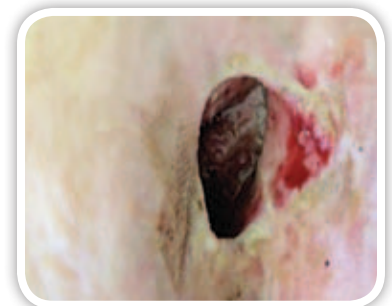
After 4 weeks using the AQUACEL™ Ag Extra™ dressing, the wound opening reduced to 3 x 2cm and the depth remained unchanged. The significant improvement was in the size of the undermining that reduced to 2cm. The wound tissue appeared to be healthy and firm, with pinkish red color and did not bleed.

The management plan was continued for another few weeks. On 8/17 the wound size was 2.5 x 1.8cm and the undermining was 1.5cm. At the proximal edge of the ulcer, a substantial growth of new tissue was noticed.

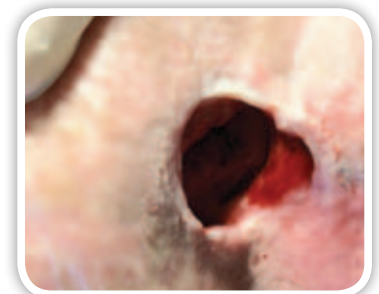
## Discussion:

Unlike some other advanced wound dressings, the AQUACEL™ Ag Extra™ dressing does not transform into a hard lumpy ball of mass, which potentially adds a source of pressure to the healing environment of delicate wound beds. The AQUACEL™ Ag Extra™ dressing transformed into a soft gel-like consistency that continued to absorb exudate, conformed to the shape and size of the wound bed, and remained intact during removal without leaving residue on the granulation tissue.

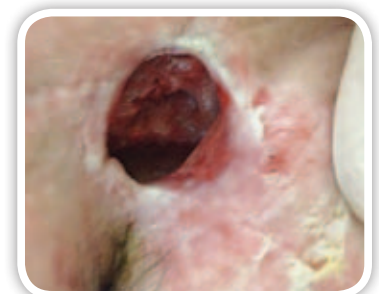
Using a visual analog scale of 1-10 to determine level of pain (10 being highest and 1 being lowest level of pain), the patient reported pain to be at level 2 during both dressing changes and while the dressing was in place. Overall, he rated the comfort of the dressing as excellent.



6/22/2012



7/06/2012



8/17/2012



# Case Study 7: Traumatic Wound

Kathryn Braun, RN, WRN, IIWCC

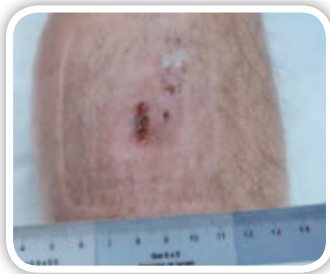
## Introduction:

This patient, G.W., is a 78 year old male who experienced a traumatic injury resulting in a fractured tibia and fibula in March 2012. The fractures were repaired by open reduction and placement of hardware. One month post-operative, he experienced a wound dehiscence which resolved with IV antibiotics and local wound care. He presented to the clinic mid-June with erythema, tenderness and warmth of the right shin which subsequently opened and began draining moderate amounts of sero-sanguinous exudate. He is a non-smoker, no nutritional issues, active for his age.

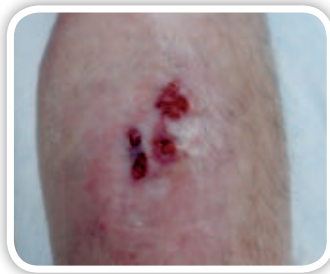Multiple superficial full thickness wounds developed within the area of erythema. At study baseline visit, all wounds measured 1.1-1.5cm in length, 0.5-1cm in width and less than 0.5cm depth. Wound beds presented with 50% granulation tissue and 50% slough. Periwound skin presented as healthy. Current management included cleansing the wound with normal saline every other day, and application of a foam bordered dressing every other day. He had a bone scan on return to Canada from the U.S. in March.

## Methodology:

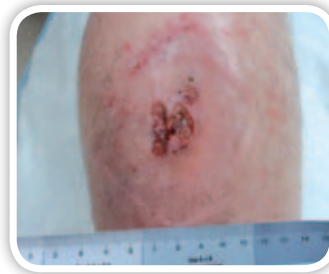On 6/29/2012, a new dressing evaluation was initiated. The wound was cleansed using saline. AQUACEL™ Ag Extra™, a new Hydrofiber™ with silver dressing, was applied as the primary dressing. AQUACEL™ foam dressings were used as the cover dressing and secured with shaped retention bandage. The frequency of dressing change remained every other day. As drainage and erythema decreased, the frequency of dressing changes was decreased to every third day.



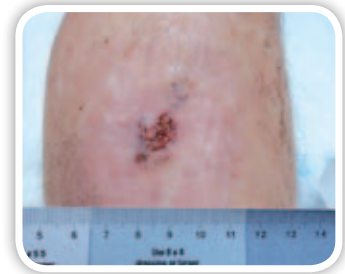6/29/2012



7/17/2012



7/24/2012



8/08/2012

## Results:

Initially, the amount of slough decreased, the granulation bed area increased and less exudate was detected. However on 7/24, drainage increased and wound surface area increased and the signs of clinical infection were once again present. A referral was made to Infectious Diseases, and the patient was placed on oral antibiotic therapy. During his 8/8 clinic visit, the size of the wound bed had decreased by approximately 2/3, and signs of clinical infection were resolving. At the final visit, the wound bed presented with 100% granulation tissue.

## Discussion:

This client turned out to have an underlying osteomyelitis, and was seen by orthopedics, plastics and Infectious Diseases at various times over the past few months. He had several relapses into inflammation/fever/increased size of wound. This contributed to a significant increase in exudate from the wound, which was well-controlled by the AQUACEL™ Ag Extra™ dressing, thus enabling us to maintain the dressing frequency rather than having to increase the frequency of dressing changes. The silver in the dressing provided adequate management of the increased number of bacteria in the wound.

# Case Study 8: Acute Wound

Kathryn Braun, RN, WRN, IIWCC

## Introduction:

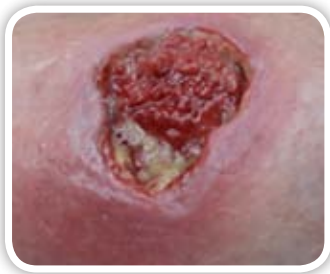A.L. is a 35 year old female who fell through a loose board in her deck 8 weeks prior to her baseline study visit. She was in good health, non-smoker, and a busy mom. She visited her doctor due to development of a large hematoma, redness, swelling and pain in the area. The superficial skin appeared to have “road rash”, however the area then developed a large hematoma. The hematoma subsequently opened & the wound was debrided during her clinic visit. She received two courses of oral antibiotics prior to wound development.

At study baseline visit, the wound measured 3.7cm in length, 2.8cm in width and 0.8cm in depth. Peri-wound erythema of less than 2cm along with 3cm induration extending beyond the wound was present on evaluation. The wound bed contained 10% slough and 90% dusky granulation tissue. Undermining of 1.5cm extended into the side of the wound at 1 o'clock. Large amounts of, pinkish-yellow, viscous seropurulent exudate was present. There was no odour.

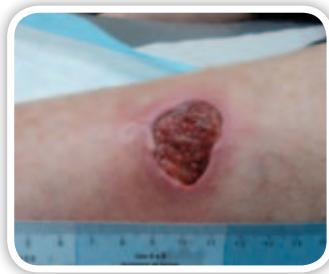Initially, the wound was cleansed with normal saline, an AQUACEL™ dressing was applied and the dressing was covered with a foam bordered dressing daily.

## Methodology:

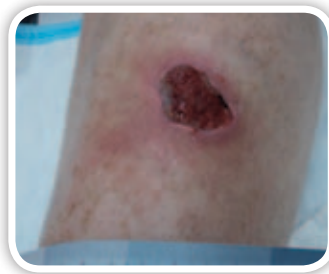On 7/03/2012, a new dressing evaluation was initiated. The wound was cleansed using saline. AQUACEL™ Ag Extra™, a new Hydrofiber™ with silver dressing, was applied as the primary dressing. AQUACEL™ Foam was applied as the secondary dressing.



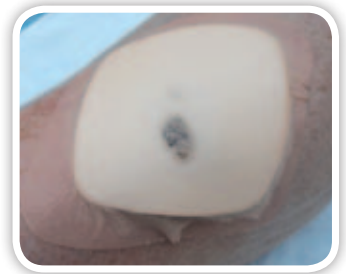7/03/2012



8/01/2012



8/14/2012



8/14/2012

## Results:

At the end of the four week evaluation, the wound showed significant progress and the decision was made to continue with the new protocol of care until no longer clinically indicated. Within the first week, the undermining had significantly decreased in area and percentage of slough was reduced. The wound had decreased in size by 25% within the first 4-weeks and an additional 15% on week 5. By week 5 the undermining was entirely gone. The wound bed now presented with 100% granulation tissue, which appeared to be a healthier red color. Wound drainage significantly decreased to the point where dressing changes were only required every four days.

## Discussion:

This patient rated the comfort of the dressing overall to be excellent. She was extremely pleased with the progress of the wound. Of note is the performance of the dressing to aid in removal of slough, even in areas of undermining. The dressing also provided excellent exudate absorption and retention, helping to maintain the fragile healing environment.

# Case Study 9: Surgical Site Infection

Kathryn Braun, RN, WRN, IIWCC

## Introduction:

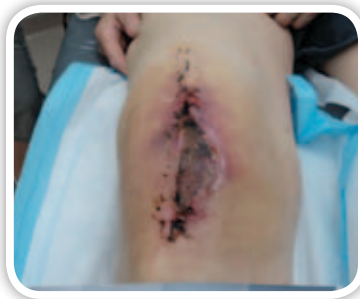G.M. is an 86 year old male who had a right total knee arthroplasty on July 6, 2012. The staples were removed on July 18. Subsequently he developed a surgical site infection and was placed on oral antibiotics. No comorbidities, non-smoker, in general good health, no nutritional issues.

At study baseline visit, the right knee presented with an infected post surgical wound measuring 9cm in length, 2.5cm in width and depth unable to be determined because the wound bed was 100% covered with necrotic tissue. The peri-wound skin was erythematous, macerated and wet. Moderate serous exudate was present.

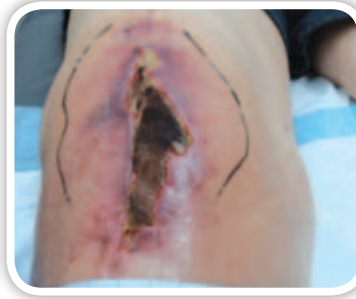Current wound management included daily cleansing with normal saline and application of a foam Border dressing.

## Methodology:

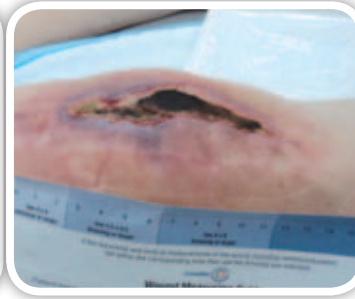
On 7/24/2012, a new dressing evaluation was initiated. The wound was cleansed using saline. AQUACEL™ Ag Extra™, a new Hydrofiber™ with silver dressing, was applied as the primary dressing. DuoDERM™ Signal was applied as the secondary dressing. The frequency of dressing changes remained daily.



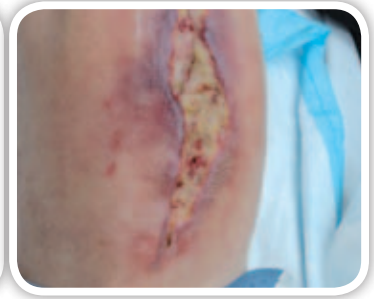
7/24/2012



8/01/2012



8/07/2012



8/14/2012

## Results:

After one week of management with the AQUACEL™ Ag Extra™ dressing, the wound bed presented with a 10% reduction in slough and reversion to granulation tissue. At week two, an additional 5% granulation tissue was noted and a marked decrease in surrounding erythema was noted. The wound was sharp debrided the day prior to this visit. Exudate had decreased and the dressing changes were reduced to every other day. At the end of three weeks, the wound showed significant progress with resolution of infection, therefore the decision was made to discontinue the AQUACEL™ Ag Extra™ dressing, and change to AQUACEL™ Extra dressing without silver. Sharp debridement continued as needed.

## Discussion:

Most significantly for this patient, the peri-wound erythema was resolved and progression of infection was controlled. Absorption and retention of exudate was good progressing to excellent. Debridement of slough was facilitated with the use of AQUACEL™ Ag Extra™ dressing.

AQUACEL, AQUACEL Extra, ConvaTec, the ConvaTec Logo, Hydrofiber and the Hydrofiber Logo are registered trademarks in the U.S. of ConvaTec Inc. All other trademarks are the property of their respective owners.

©2012 ConvaTec Inc.

AP-013089-MM



**AQUACEL™ Dressings**  
TRIED. TRUE. TRUSTED.™