

Diabetic foot ulcers

Compared to saline moistened gauze

- "...[AQUACEL® dressing]... may be preferable not only in terms of efficacy, but also in terms of safety"

Study details

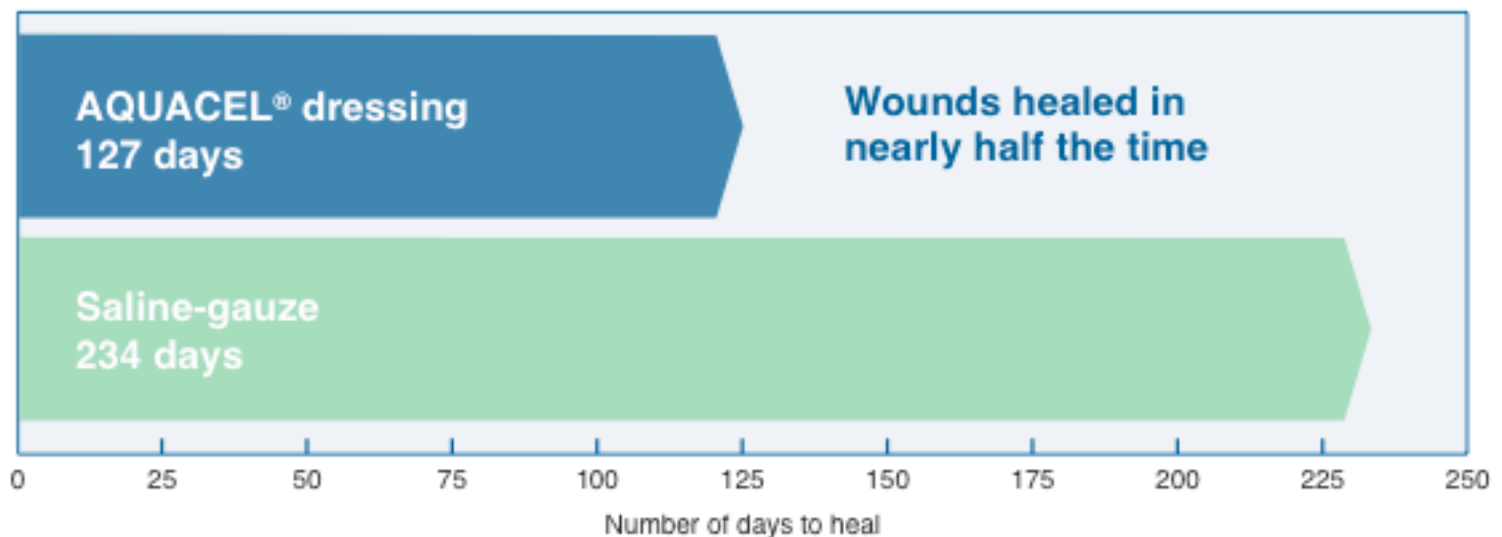
Publication	Sodium carboxyl-methyl-cellulose dressings in the management of deep ulcerations of diabetic foot. Piaggese A, Baccetti F, Rizzo L, Romanelli M, Navalesi R, Benzi L. Diabetic Medicine 2001;18:320-324
Number of patients	20
Inclusion criteria	Age 18-75 years, type 1 or type 2 diabetes for over 5 years, foot ulcerations for more than 3 weeks, >1cm wide and 1cm deep, good peripheral blood supply, with palpable peripheral pulses or an ankle-brachial pressure index >0.9
Wound type	Ulcers due to diabetic neuropathy, or surgical drainage of a previous infection, or both

Design

A study of outpatients with diabetic foot ulcers attending a foot clinic, comparing AQUACEL® dressing with saline moistened gauze.

Results

- AQUACEL® dressing contributed to significantly faster healing than saline moistened gauze (127 days versus 234 days) (P<0.001)
- Rate of granulation and reduction in lesional volume were significantly better in ulcers managed with AQUACEL® dressing than those managed with saline moistened gauze (60% and 50% vs 32.5% and 35%, respectively)
- Patients managed with AQUACEL® dressing underwent dressing changes on average every 2.1 days compared to 2.4 days for patients managed with saline-moistened gauze



Conclusion

"...[AQUACEL®]... dressing were shown to be safe, effective and well tolerated in the management of non-ischaemic, non-infected deep diabetic foot ulcers."