

Diabetic foot ulcers

In chronic wounds previously managed with moistened gauze compress, 92% of wounds managed with AQUACEL[®] dressing healed or improved

Study details

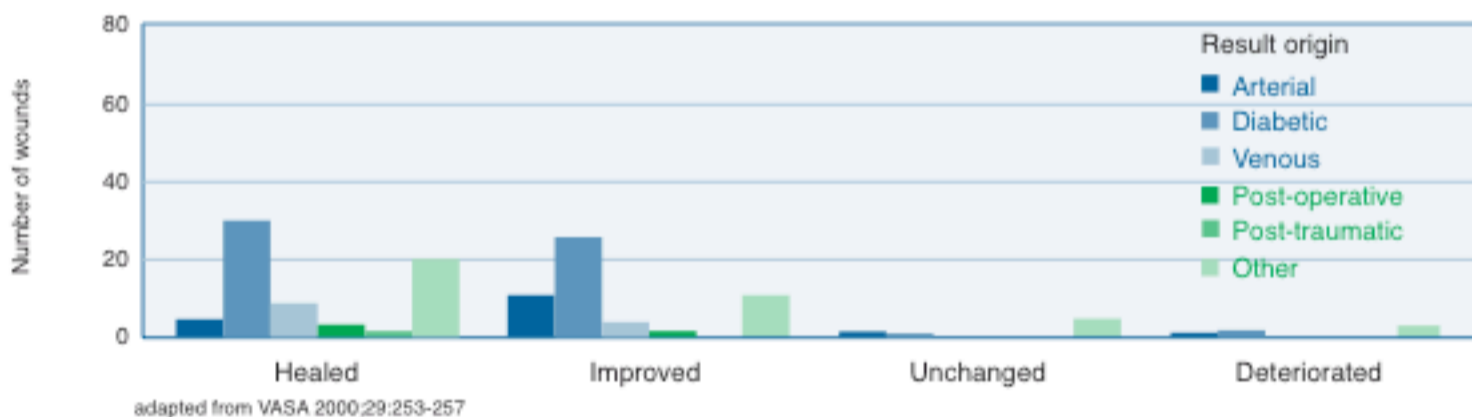
Publication	Experiences with hydrofibres in the moist treatment of chronic wounds, in particular of diabetic foot. Brummer U, Eberlein Th. VASA 2000;29:253-257
Number of patients	108
Inclusion criteria	Information not available
Wound type	Chronic wounds, particularly diabetic foot ulcers

Design

In a retrospective review carried out between autumn 1996 and summer 1998, patients with 135 chronic wounds which had previously been managed with a moistened gauze compress and which had existed for between 3 months and 45 years were managed with a protocol of care incorporating AQUACEL[®] dressing.

Results

Detailed overview of therapeutic results according to wound origin (135 wounds in total)



- 92% of wounds were influenced positively during the course of the study

Conclusion

“The analysis of the total group of patients allows the conclusion that modern moist wound treatment with [AQUACEL[®] dressing] can provide a useful addition to the spectrum of wound therapy, offering prospects of success regardless of the origin of the wounds.”