

Prospective Assessment and Classification of Stoma Related Skin Disorders

Vera Allyn (Lynette) Scott CMSRN, COCN; Debra Raasch APNP; Gregory Kennedy MD, PhD;
Charles P. Heise MD, University of Wisconsin School of Medicine and Public Health,
Section of Colon and Rectal Surgery

Introduction

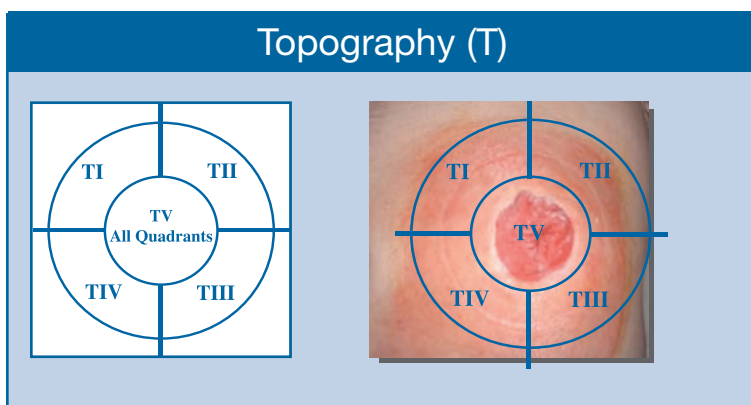
Peristomal skin is at risk for multiple skin disorders. By utilizing a standard peristomal skin assessment instrument, clinicians and WOCNs can interact when reporting and monitoring these complications. In addition, an evaluation of the topography, extent and location of these skin disorders may allow optimal management of peristomal skin integrity and further assist the surgeon with ideal stoma placement. We sought to evaluate and categorize all stoma related skin complications in a prospective manner.

Methods

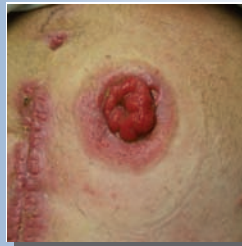A prospective, ongoing observational study was conducted in which surgical patients with an ileostomy, a colostomy or urostomy were assessed post-operatively and on a regular basis thereafter as determined by the patient or home care nurse. The Italian skin disorder classification instrument¹ was utilized to document the type of lesion and location of skin breakdown beneath the skin barrier by the WOCN or Nurse Practitioner. The data was analyzed for commonalities as related to lesion type, frequency and occurrence with respect to specific location.

Topography of Peristomal Skin Lesions (T)

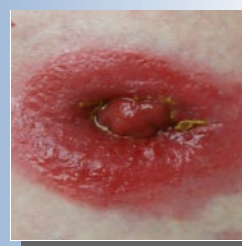Topography identifies the area affected. The classification can include more than one "T". Topography is from the Nurse or healthcare provider's perspective, standing directly in front of and facing the patient.



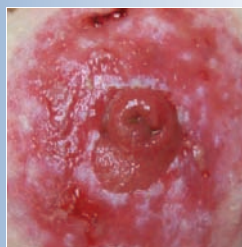Skin Lesion Types (L)



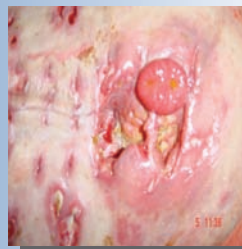L1 Hyperemic: skin erythema



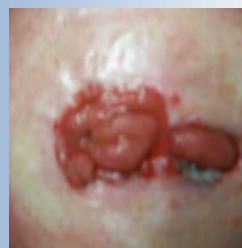L2 Erosive: not beyond dermis



L3 Ulcerative: erosion beyond the dermis



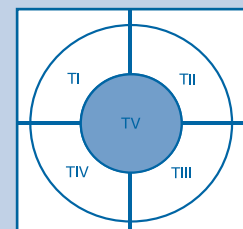
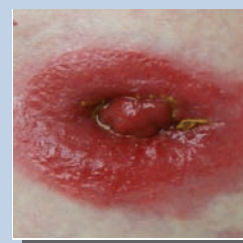L4 Ulcerative: fibrinous/necrotic



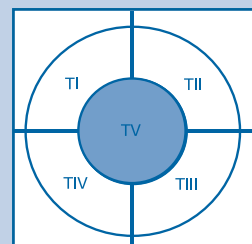
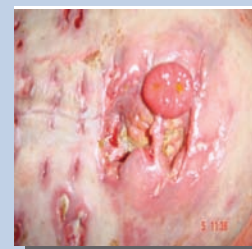LX Proliferative: granulomas, oxalate deposits, neoplasms

Examples of Classifying a Peristomal Lesion According to the Peristomal Skin Instrument

L2-TV
Erosive lesion with loss of substance not extending beyond the dermis on all quadrants.



L4-TV
Ulcerative lesion fibrinous/necrotic



1. Bosio G, Oisani F, Lucibello L, et. al. A proposal for classifying peristomal skin disorders: Results of a multicenter observational study. *Ostomy Wound Manage.* 2007; 53(9): 38-43.

Results

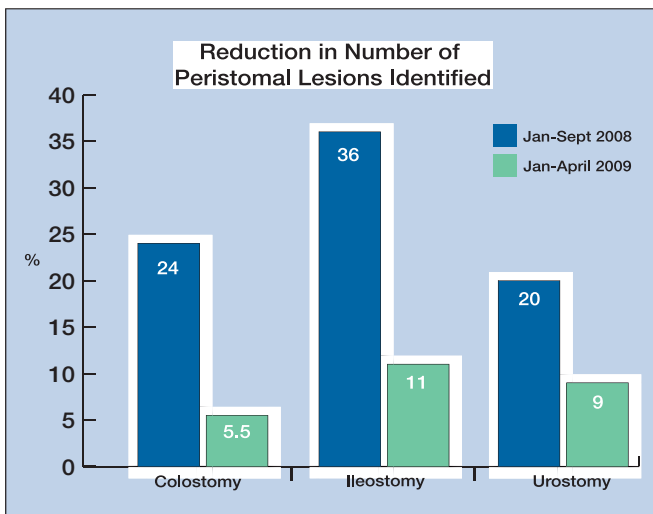
This study was initiated in January 2008. From January through September, 405 patients with surgically placed stomas received care by a WOCN. There were 209 ileostomies, 105 colostomies and 91 urostomies. Of these, skin complications were noted in 36% of ileostomies, 24% of colostomies and 20% of urostomies. Data was collected on average at 12.5 days post op. The majority of lesions noted were categorized as hyperemic or erosive (L1 or L2). When considering only ileostomy lesions, most (60%) were found to involve the inferior peristomal skin quadrants (TIII and TIV).

During October through December 2008, this facility converted from a cut-to-fit skin barrier to a moldable technology skin barrier pouching system* as the standard post-operative pouching system. The most recent statistics (January through April 2009) reflect a marked reduction in the number of peristomal lesions identified (See Figure 1 and Figure 2). A total of 471 patients with surgically placed stomas received care by a WOCN. There were 230 ileostomies, 164 colostomies and 77 urostomies. Of these, skin complications were noted in 11% of ileostomies, 5.5% of colostomies and 9% of urostomies. This data refers to a 12.5 day post op assessment.

Figure 1

	Cut-to-Fit Results		Moldable Technology* Results		Variance
	Number (N)	% Skin Lesions	Number (N)	% Skin Lesions	Reduction in Lesions
Ileostomy	209	36%	230	11%	69%
Colostomy	105	24%	164	5.5%	77%
Urostomy	91	20%	77	9%	55%

Figure 2



Conclusions

By utilizing a peristomal skin disorder instrument, the prevalence of stoma related skin complications can be categorized. This data suggests that ileostomies are associated with a higher incidence of skin complications; and most are found in the inferior quadrants. WOCNs, nursing staff and surgeons should consider these findings when marking or creating a stoma.

Sponsored by ConvaTec Inc.

Product Notation

*SUR-FIT Natura® Moldable Stomahesive® Skin Barrier with Hydrocolloid Flexible Flange

SUR-FIT Natura and Stomahesive are registered trademarks of ConvaTec Inc.