

Implementation of Wound Hygiene in clinical practice: early use of an antibiofilm strategy promotes positive patient outcomes

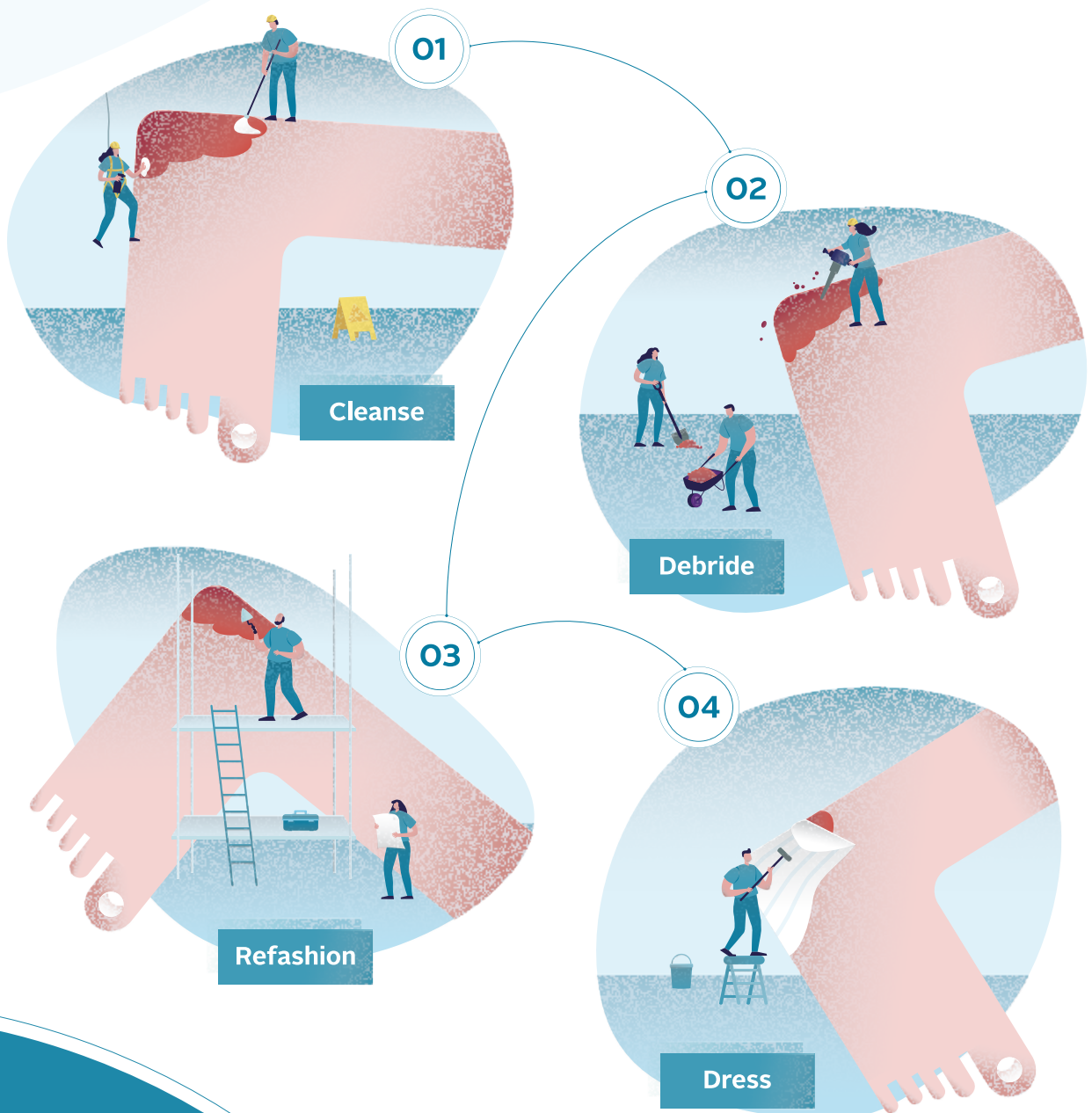


Table of contents

Wound Hygiene: a simple and intuitive concept that improves healing outcomes

Chris Murphy

S3

Case studies

Case study 1: leg ulcer

S8

- Beata Mrozikiewicz-Rakowska, Izabela Kuberka, Leszek Czupryniak

Case study 2: diabetic foot ulcer

S10

- Beata Mrozikiewicz-Rakowska, Leszek Czupryniak

Case study 3: infected insect bite

S13

- Paz Beaskoetxea Gómez, Melina Vega de Ceniga

Case study 4: surgical wound—diabetic foot stump

S15

- Melina Vega de Ceniga, Paz Beaskoetxea Gómez

Case study 5: non-healing traumatic wound

S17

- Angela Walker

Case study 6: diabetic foot ulcers

S18

- Angela Walker

Case study 7: hard-to-heal wound on the Achilles tendon

S20

- Annabelle Tomkins

Case study 8: arterial leg ulcer

S21

- Angela Walker

Case study 9: leg ulcer on a patient with diabetes

S23

- Jenny Hurlow

Case study 10: neuropathic diabetic foot ulcer

S25

- Raymond Abdo

Case study 11: surgical wound

S27

- Sara Sandroni, Elisa Marinelli

Case study 12: traumatic wound

S29

- Sara Sandroni, Elisa Marinelli

Declaration of interest

This supplement was commissioned and supported by ConvaTec Limited. All authors are independent practitioners who were paid a fee for their contributions. Chris Murphy is a speaker for ConvaTec and member of its Wound Hygiene advisory board. Jenny Hurlow is a clinical consultant for ConvaTec. Izabela Kuberka, Beata Mrozikiewicz-Rakowska and Melina Vega de Ceniga have received payment from ConvaTec to present webinars on Wound Hygiene. Paz Beaskoetxea is a speaker for ConvaTec. Leszek Czupryniak, Annabelle Tomkins and Angela Walker have no interest to declare.

Editor and associate publisher, medical education: Tracy Cowan
Head of projects: Camila Fronzo
Project manager: Mercedes Arrieta
Design: Fonthill Creative
Managing director: Anthony Kerr: anthony.kerr@markallengroup.com

Published by: MA Healthcare Ltd, St Jude's Church, Dulwich Road, London, SE24 0PB, UK
Tel: +44 (0)20 7738 6726 Web: www.markallengroup.com
© MA Healthcare Ltd 2022

ConvaTec, the ConvaTec logo, the Wound Hygiene logo and the cover artwork are trademarks or registered trademarks or copyrighted materials of ConvaTec Inc. Any use without the express written consent of ConvaTec Inc. is forbidden. All rights reserved

Wound Hygiene: a simple and intuitive concept that improves healing outcomes

Non-healing wounds are devastating for patients, potentially causing long-term morbidity and an impaired quality of life. They also incur a huge health economic burden for health-care services. Understanding of the causes of non-healing wounds has increased significantly. While the need to address the underlying aetiology has always been acknowledged, the role of biofilm in delaying or preventing healing is now accepted. There is a consensus on the need to debride the wound to remove biofilm and then prevent its reformation, to kickstart healing. The potential benefits of incorporating an antibiofilm component within the wound bed preparation framework are clear. However, such a strategy needs to be flexible enough so that it can be implemented by all practitioners, regardless of their expertise or specialty. Wound Hygiene does this. This supplement describes the Wound Hygiene protocol, and includes a selection of case studies on different wound types, demonstrating its ease of use and effectiveness in clinical practice.

Chris Murphy Nurse Specialist, Vascular Wounds, The Ottawa Hospital Limb Preservation Centre, Ottawa, Canada



The need to target potentially treatable health-care conditions is now greater than ever. Non-healing wounds add greatly to the demands on severely strained health-care resources worldwide. The prevalence of hard-to-heal wounds is increasing in tandem with a rise in contributory conditions such as diabetes, peripheral arterial disease, obesity, cardiovascular disease and an ageing population. The escalating cost of diabetic foot ulcer (DFU) care has been compared with that of cancer care.^{1,2} There is growing evidence of increases in wound-related disability, morbidity, mortality and reduced quality of life. It has been estimated that up to 50% of people who undergo major amputation following diabetic foot ulceration may die within 5 years.^{3,4}

The growing burden of hard-to-heal wounds is becoming difficult to ignore, as it places considerable strain on health-care systems worldwide. Venous leg ulceration has been reported to affect 1% of the population⁵ and the global prevalence of diabetic foot ulceration is calculated as 6.3%.⁶ In 2014, the estimated cost to the US national health insurance programme, Medicare, for acute and chronic wounds was \$28.1–96.8 billion.⁷ In the UK, in 2017–18, 3.8 million patients treated by the NHS were reported to have a wound, incurring an estimated £8.3 billion cost for their management, of which £5.6 billion was associated with non-healing wounds. Most of this cost (81%) was incurred in the community.⁸ The cost and strain imposed by non-healing wounds on care providers—along with the use of antibiotics to treat wound-related infection, which contributes to global over-usage,⁹—is a matter of international concern.

Efforts must be made not to accept this state of affairs. Non-healing wounds have commonly been described as ‘chronic wounds’ in clinical practice and academic circles, but this term may affect care delivery. Although ‘chronic wound’ accurately describes a condition that is present for a long time period, for those unfamiliar with current wound-healing strategies the connotation is that the wound will be everlasting and healing may not be an expectation. Therefore, use of this term may be detrimental to wound-service policies, funding and resources, and could inadvertently reduce access to the expertise required to heal a complex wound. Thus, becoming comfortable with the label ‘chronic’ may discourage practitioners from questioning why a wound is not healing, adding to the number of unhealed wounds requiring ongoing care. A more proactive term that describes the challenge required is ‘hard-to-heal’.¹⁰

This article describes the key role played by wound biofilm in delaying or stalling healing and how incorporating an antibiofilm strategy into wound bed preparation can improve outcomes.

Biofilm: the enemy within

In recent years, scientists have uncovered an invisible enemy that is present in the majority of hard-to-heal wounds.^{11–13} This enemy is biofilm, which comprises a tenacious army of bacteria that is impervious to common wound irrigation practices, such as the use of light irrigation and/or saline irrigation.¹⁴ Biofilm is an ever-present, yet hidden, barrier to wound healing, and its eradication is now widely acknowledged as a previously unmet requirement for successful healing outcomes.^{12,13}

The presence of biofilm creates a constant state of low-grade inflammation as the body tries ineffectively to rid itself of the pathogenic polymicrobial community. These adapted low-metabolism bacteria settle in the open wound and produce a polymeric protective barrier in preparation for a long-term stay. Many antimicrobial dressings are unable to penetrate this barrier and disrupt the biofilm. Therefore, a considered strategy that can overcome this challenge may be necessary to achieve effective results.^{15,16}

Biofilm is the preferred state for bacteria and is often multi-species. The type and proportions of the bacterial species within the community, their virulence and vulnerability to dispersal will vary with every wound. However, a consistent physical approach has been found to be effective for its removal.^{17,18} This physical approach needs to be vigorous. A practitioner who was instrumental in the development of the Wound Hygiene concept described in this article, anecdotally explained it thus, 'before we were aware of biofilm in wounds, we were taught to use a gentle approach, to think of wounds as a "flower garden" to be nurtured with minimal touch. But now we know that biofilm, like weeds, overgrows the healing environment, and a stronger, more proactive strategy is needed [to eliminate it].'

Developing an antibiofilm strategy

In September 2019, a group of international wound practitioners with clinical and scientific expertise formed an expert panel that met in the UK to discuss how to reduce the burden of non-healing wounds worldwide.¹⁰ At the meeting, they were asked to describe the challenges encountered when faced with hard-to-heal wounds in their respective countries and to identify specific issues they had observed in their own practice.

Although the panel came from varied backgrounds, a commonality of perspective quickly became apparent. All the expert panel members accepted that wound bed preparation was the foundation for effective wound care, although they believed it was rarely implemented in practice. Barriers discussed were lack of resources and administrative support, lack of competency, concerns about patient safety, an attitude that 'chronic' wounds are unlikely to heal, time constraints and a belief that doing nothing equates to 'doing no harm'.

Aspects of wound bed preparation, and its vital importance in delivering effective wound care, have been well described in several international best practice documents.^{19,20} In addition, there is international agreement that standard of care constitutes addressing the underlying wound aetiology, engaging the patient and taking their perspective on board, acknowledging the social determinants of health, and providing evidence-informed wound care.^{19,20}

Therefore, it is interesting that, according to the expert panel, many practitioners appear to think it is acceptable

to omit wound bed preparation (foundational care) if there are logistical barriers to its implementation in the workplace. As such, the panel proposed that consistent, repetitive, basic wound bed preparation is rarely available to patients with hard-to-heal wounds. Instead, for practical reasons, there is often a common focus on dressing selection and fast transactional care. However, the group agreed that, without proper wound bed preparation, such treatments are unlikely to facilitate healing.

The panel concluded that this lack of foundational care must be addressed and that the revelation that biofilm may be the reason for non or delayed healing must be considered in care planning.

In recent years, wound biofilm has been recognised as the invisible enemy that may be thwarting expectations of healing, with several studies concluding that it is present in most hard-to-heal wounds.^{12,21} During the expert panel meeting, there was much scientific discussion that the continuous presence of biofilm within a wound causes prolonged and unrelenting inflammation, which manifests as ongoing chronic infection; this may present only with subtle signs and is not primarily suitable for antibiotic eradication. As biofilm recurs within hours, even after wound cleansing and debridement, the panel agreed that wound bed preparation needs to be performed repetitively if it is to effectively target the biofilm, and thus improve healing rates and reduce the burden on health-care systems. They considered that an intuitive term was required to describe a practical strategy for managing hard-to-heal wounds that has an antibiofilm component at its heart.¹⁰

Wound Hygiene

Hygiene is a recognised term that describes an expectation that regular decontamination and maintenance of a clean standard will promote health. The promotion of healthy wound tissue is likely to be the most effective method of facilitating wound healing. Therefore, the concept of Wound Hygiene, which is designed to promote healthy tissue, was born.

The use of hygiene to remove biofilm in a repetitive and proactive manner and thus improve health and reduce the burden of disease is well documented in dentistry. The twice-daily regimen of cleaning our teeth with a brush and the purposefully designed cleansing solution that is toothpaste is well known to citizens of the world. This repetitive hygiene is necessary as biofilm reformation starts within hours of brushing, with lack of repeated brushing likely to result in dental complications.

This inspired the conception of the Wound Hygiene framework. A consistent, repetitive and skilled approach designed to support wound healing, the framework has become a focus for the expert group's work. The term 'hygiene' was felt to be intuitive, as it is suggestive of a requirement for a regular and required procedure. From there, the panel explored what actions the Wound Hygiene concept should comprise.

Components of Wound Hygiene

Wound Hygiene is a simple concept that can be safely implemented, to some degree, by any practitioner—specialist or generalist—in any setting. It must be performed routinely, with the first implementation taking place after the initial holistic assessment and diagnosis of the underlying aetiology, in accordance with recommendations for best practice, and then at every dressing change. A full protocol for the four steps of Wound Hygiene was published in a JWC consensus document.¹⁰

Wound Hygiene should be included in local policies to improve practitioner confidence and avoid patient harm. Training should be provided to practitioners on how to implement the concept safely, based on their level of competency.

The four components of Wound Hygiene are to cleanse, debride, refashion and dress the wound. These components can be implemented alongside the recommendations of wound frameworks such as TIMERS²² and the Wound Management Cycle,²³ which form the basis of more wound-specific guidance on, diabetic foot ulcers, venous leg ulcers and pressure ulceration.²⁴ When implementing Wound Hygiene, practitioners should adhere to their local policies in line with their clinical competencies, scope of practice, knowledge, skills and judgement.

Step 1: cleanse

Indicated for all wounds, this can be performed by any practitioner and involves use of a cleansing solution (Fig 1). To diminish biofilm, an antimicrobial solution designed for wound and skin care that contains a surfactant +/- antibiofilm technology should be used.^{10,25} This should be applied with sufficient effort to physically remove contaminants. Saline has been found to be of limited effect in removing biofilm.^{14,26}

Most cleansing solutions will require some dwell time or soaking to solubilise debris and assist biofilm removal. This is often done by soaking gauze in the solution until it is dripping wet, and leaving it in the wound while preparing the dressing tray and equipment for the dressing change. It is important to follow manufacturer's instructions and be aware of the amount of solution that needs to be used. Purposeful cleansing of the wound and 10–20 cm of periwound skin is recommended to improve local decontamination. Cytotoxic solutions, such as full-strength povidone-iodine and hydrogen peroxide, may not be suitable for this purpose.²⁷

Step 2: debride

Debridement involves the physical removal of biofilm, devitalised tissue and debris and organic matter (Fig 2). The wound must be decontaminated by cleansing before and after debridement to reduce the amount of bacteria in the region. Debridement-associated pain must be anticipated and managed. Informed consent must be gained from the patient.

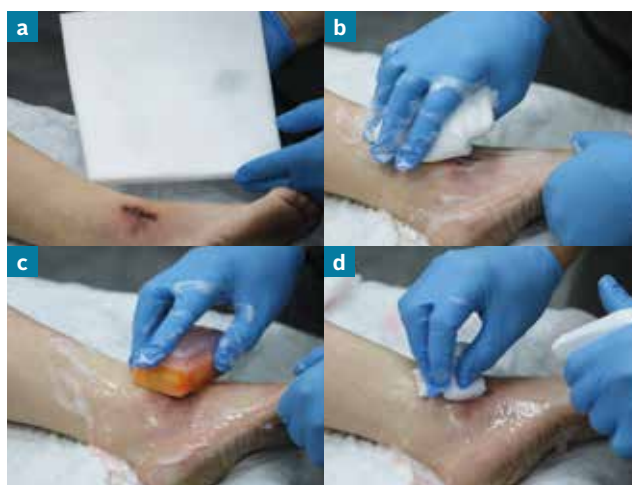

Fig 1. Step 1: cleanse

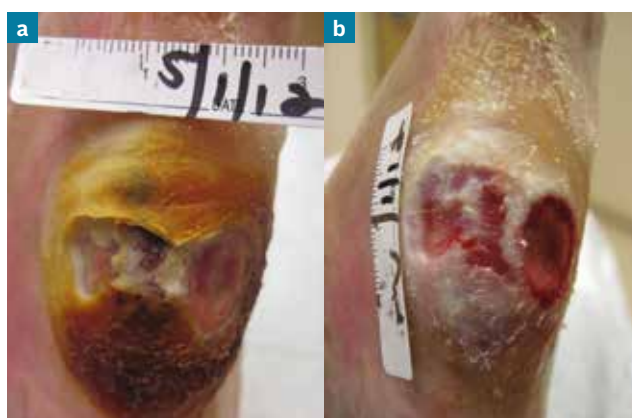

Fig 2. Step 2: debride (pre- and post)

Anyone can perform wound debridement, but the method selected will depend on the training and competencies of the practitioner. Sharp or surgical debridement should be performed by a qualified practitioner in accordance with local policies. When this is not possible, mechanical debridement, achieved by simply rubbing with gauze or using a debridement pad, is a good alternative, if sufficiently comfortable for the patient. A little (and repetitive) debridement is better than no debridement at all. If necessary, the patient can be referred for more intensive debridement.

Not having access to debridement tools is comparable to not having access to dental hygiene procedures: build-up of invisible biofilm may contribute to wound healing failure and poor outcomes, including infection. Therefore, it is recommended that wound management should involve safe debridement. Tools used for debridement in Wound Hygiene are listed in Table 1.

Autolytic debridement is not considered suitable for Wound Hygiene. It liquefies wound debris and cellular waste products, so that they are naturally removed. However, this is unlikely to remove biofilm effectively or improve the wound environment for healing.¹⁰

Table 2 lists contraindications and precautions for debridement within Wound Hygiene. For patients with bleeding disorders or on anticoagulation therapy, the wound diagnosis must be known and any diagnostic contraindications, such as inflammatory or malignant conditions, considered. Expert assessment must be performed to determine benefit versus risk by the accredited practitioner.²⁸ Acute infection requires rapid holistic management. Always refer to local policies and seek advice or a referral for any unconfirmed conditions.

Wound Hygiene protocols can still be implemented in patients for whom debridement and edge refashioning is contraindicated. In such instances, the protocol comprises cleansing and application of dressing.

Step 3: refashion

The wound edges are a primary harbour for biofilm bacteria.²⁹ Removal of biofilm, devitalised tissue, callus,

hyperkeratotic debris and senescent cells at the wound edges facilitates epithelialisation and wound contraction. To achieve this, the wound edges need to be debrided to the extent that pinpoint bleeding occurs, where local practice, patient tolerance and consent allow it.¹⁰ This agitation will stimulate expression of growth factors to kickstart the formation of healthy skin.¹⁰ Refashioning therefore requires the use of sharp debridement, or soft debridement pads or gauze (Fig 3), depending on the appearance of the wound edges and the competencies of the practitioner.

Wound edges may be like a steep 'cliff' (Fig 4) or gentle 'beach' (Fig 5) in appearance. 'Cliffs' will usually require sharp debridement, whereas 'beaches' may respond to local mechanical attention such as rubbing with gauze. As with debridement, to reduce any local bacteria, the edges should be cleansed before and after being refashioned. Again, patient consent is required.

Step 4: dress

On completion of steps 1–3, there is a window of opportunity in which to remove any residual biofilm and

Method	Tools required	Competency required
Mechanical	Soft debridement or gauze	No
Sharp	Curette Scalpel Forceps	Yes
Surgical	Minor surgical tray	Yes
Low-frequency ultrasound	Specialist device	Yes

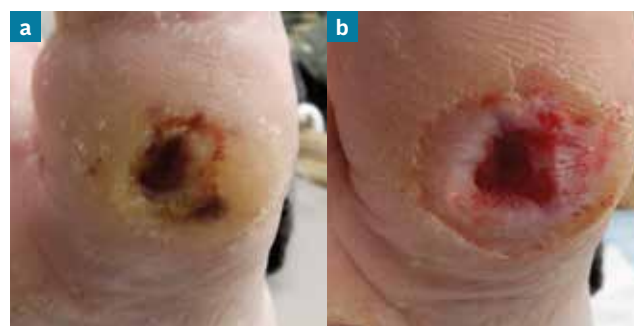

Fig 3. Step 2: refashion (pre- and post)

Contraindications	Precautions for debridement that can cause bleeding*	Other precautions
Wound aetiology is unknown	Bleeding disorders	Patients in intolerable or unavoidable pain
Acute infection	Anticoagulation therapy	Patients with a palliative condition where healing is not the ultimate goal
Inadequate perfusion		Patients with biologics, such as extracellular matrix products, in situ (as could result in removal of the product)
Inflammatory or malignant conditions such as: <ul style="list-style-type: none"> • Critical ischaemia • Pyoderma gangrenosum • Gangrene (wet or dry) • Calciphylaxis • Vasculitis • Malignant wounds 		

*Debridement may induce bleeding

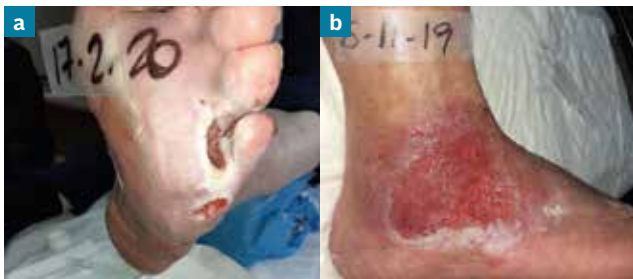

Fig 4. Cliffs (a) and beaches (b)

prevent its reformation. This involves application of a dressing that will maintain a healthy wound environment, until the next episode of care.

Although antibacterial dressings may kill planktonic bacteria, not all will penetrate and disrupt biofilm.¹⁷ Antibiofilm technologies are not only antimicrobial, but also may include multiple antibiofilm properties—that is, will dismantle, kill and repel the biofilm. Important properties for a dressing are the ability to penetrate and dismantle the polymer matrix that protects the biofilm bacteria from insult, kill the tenacious biofilm bacteria within it and prevent biofilm reformation. A combination of these attributes is likely to be most successful.

It may be appropriate to step-up or step-down dressing technologies, based on the appearance of the wound, duration of care and healing response. It is important, therefore, to assess the wound and the effectiveness of the dressing every 2–4 weeks. An antibiofilm dressing should only be used for as long as it is indicated, after which action should be taken to step down to either a non-antibiofilm or a non-antimicrobial dressing. However, the Wound Hygiene protocol should continue to be applied at every dressing change until full healing, as it is a fundamental element of care.

Anecdotal evidence from around the world indicates that Wound Hygiene is not time-consuming to perform once it becomes a routine component of wound care.

Conclusion

In dentistry, hygiene is globally accepted and its omission unthinkable. In hard-to-heal wounds, omission of hygiene results in stalled wound healing, high demands on clinical services, more antibiotic prescriptions and the increased cost—financial and psychological—of living with a wound without an end in sight. Benefits of Wound Hygiene could include lower infection rates, reduced antibiotic usage and improved healing rates, faster healing times and better patient quality of life and care experience. Cost savings can be achieved by reducing the hospital length of stay for wound complications and emergency room visits.

All members of the expert panel identified that Wound Hygiene is a practical and targeted way of improving wound outcomes. Essential to this is that it is a simple and intuitive concept that can be safely implemented, at

some level, by trained clinical practitioners with the right competencies and support, in any setting: be it the home, long-term or residential care, in outpatient clinics or acute care settings.

- Barshes NR, Sigireddi M, Wrobel JS et al. The system of care for the diabetic foot: objectives, outcomes, and opportunities. *Diabet Foot Ankle*. 2013;4. <https://doi.org/10.3402/dfa.v4i0.21847>
- Armstrong DG, Swerdlow MA, Armstrong AA et al. Five year mortality and direct costs of care for people with diabetic foot complications are comparable to cancer. *J Foot Ankle Res*. 2020;13(1):16. <https://doi.org/10.1186/s13047-020-00383-2>
- Moulik PK, Mtonga R, Gill GV. Amputation and mortality in new-onset diabetic foot ulcers stratified by etiology. *Diabetes Care*. 2003; 26(2):491–4. <https://doi.org/10.2337/diacare.26.2.491>
- Huang Y-Y, Lin C-W, Yang H-M et al. Survival and associated risk factors in patients with diabetes and amputations caused by infectious foot gangrene. *J Foot Ankle Res*. 2018;11:1. <https://doi.org/10.1186/s13047-017-0243-0>
- Posnett J, Gottrup F, Lundgren H et al. The resource impact of wounds on health-care providers in Europe. *J Wound Care*. 2009;18(4):154–61. <https://doi.org/10.12968/jowc.2009.18.4.1607>
- Zhang P, Lu J, Jing Y et al. Global epidemiology of diabetic foot ulceration: a systematic review and meta-analysis. *Ann Med*. 2017;49(2):106–16. <https://doi.org/10.1080/07853890.2016.1231932>
- Sen CK. Human wounds and its burden: an updated compendium of estimates. *Adv Wound Care (New Rochelle)*. 2019;8(2):39–48. <https://doi.org/10.1089/wound.2019.0946>
- Guest JF, Fuller GW, Vowden P. Cohort study evaluating the burden of wounds to the UK's National Health Service in 2017/2018: update from 2012/2013. *BMJ Open*. 2020;10(12):e045253. <https://doi.org/10.1136/bmjopen-2020-045253>
- Bowler P, Murphy C, Wolcott R. Biofilm exacerbates antibiotic resistance: Is this a current oversight in antimicrobial stewardship? *Antimicrob Resist Infect Control*. 2020;9(1):162. <https://doi.org/10.1186/s13756-020-00830-6>
- Murphy C, Atkin L, Swanson T et al. Defying hard-to-heal wounds with an early antibiofilm intervention strategy: wound hygiene. *J Wound Care*. 2020; 29(Sup3b):S1–26. <https://doi.org/10.12968/jowc.2020.29.Sup3b.S1>
- Bowler PG, Duerden BI, Armstrong DG. Wound microbiology and associated approaches to wound management. *Clin Microbiol Rev*. 2001;14(2):244–69. <https://doi.org/10.1128/CMR.14.2.244-269.2001>
- James GA, Swogger E, Wolcott R et al. Biofilms in chronic wounds. *Wound Repair Regen*. 2008;16(1):37–44. <https://doi.org/10.1111/j.1524-475X.2007.00321.x>
- Dowd SE, Sun Y, Secor PR et al. Survey of bacterial diversity in chronic wounds using Pyrosequencing, DGGGE, and full ribosome shotgun sequencing. *BMC Microbiology*. 2008;8(1):43. <https://doi.org/10.1186/1471-2180-8-43>
- Kanno E, Tanno H, Suzuki A et al. Reconsideration of iodine in wound irrigation: the effects on *Pseudomonas aeruginosa* biofilm formation. *J Wound Care*. 2016; 25(6):335–9. <https://doi.org/10.12968/jowc.2016.25.6.335>
- Metcalf D, Parsons D, Bowler P. A next-generation antimicrobial wound dressing: a real-life clinical evaluation in the UK and Ireland. *J Wound Care*. 2016; 25(3):132, 134–8. <https://doi.org/10.12968/jowc.2016.25.3.132>
- Bowler PG. Antibiotic resistance and biofilm tolerance: a combined threat in the treatment of chronic infections. *J Wound Care*. 2018;27(5):273–7. <https://doi.org/10.12968/jowc.2018.27.5.273>
- Parsons D, Meredith K, Rowlands VJ et al. Enhanced performance and mode of action of a novel antibiofilm Hydrofiber® wound dressing. *BioMed Research Int*. 2016;2016:e7616471. <https://doi.org/10.1155/2016/7616471>
- Wolcott RD, Rumbaugh KP, James G et al. Biofilm maturity studies indicate sharp debridement opens a time-dependent therapeutic window. *J Wound Care*. 2010; 19(8):320–8. <https://doi.org/10.12968/jowc.2010.19.8.77709>
- Orsted HL, Keast DH, Forest-Lalonde L et al. Best practice recommendations for the prevention and management of wounds In: Foundations of best practice for skin and wound management. A supplement of wound care Canada 2017. <https://tinyurl.com/4zb8697m> (accessed 9 June 2021)
- European Wound Management Association (EWMA). Position document: wound bed preparation in practice. London, 2004. <https://tinyurl.com/4nxdetb9> (accessed 9 June 2021)
- Percival SL, McCarty SM, Lipsky B. Biofilms and wounds: an overview of the evidence. *Adv Wound Care (New Rochelle)*. 2015;4(7):373–81. <https://doi.org/10.1089/wound.2014.0557>
- Atkin L, Bučko Z, Conde Montero E et al. Implementing TIMERS: the race against hard-to-heal wounds. *J Wound Care*. 2019;23(Sup3a):S1–50. <https://doi.org/10.12968/jowc.2019.28.Sup3a.S1>
- Bassett K, Orsted H. Enabling best practice using the wound prevention and management cycle. *Wounds International*. 2017;8(2):32–3.
- Registered Nurses' Association of Ontario (RNAO). Clinical best practice guidelines. Assessment and management of pressure injuries for the interprofessional team. 3rd ed. Toronto, 2016. <https://tinyurl.com/22ca7mc8> (accessed 9 June 2021)
- Percival SL, Mayer D, Malone M et al. Surfactants and their role in wound cleansing and biofilm management. *J Wound Care*. 2017;26(11):680–90. <https://doi.org/10.12968/jowc.2017.26.11.680>
- Phillips PL, Yang Q, Schultz GS. The effect of negative pressure wound therapy with periodic instillation using antimicrobial solutions on *Pseudomonas aeruginosa* biofilm on porcine skin explants. *Int Wound J*. 2013;10 Suppl 1:48–55. <https://doi.org/10.1111/iwj.12180>
- Ovens L, Irving S. Advances in wound cleansing: an integrated approach. *Wounds UK*. 2018;14(1):58–63.
- Rodd-Nielsen E, Brown J, Brooke J, Fatum H, Hill M, Morin J, St-Cyr L. Evidence-based recommendations for conservative sharp wound debridement. Canadian Association for Enterostomal Therapy (CAET) 2011. <https://tinyurl.com/ynjddar2> (accessed 9 June 2021)
- Bay L, Kragh KN, Eickhardt SR et al. Bacterial aggregates establish at the edges of acute epidermal wounds. *Adv Wound Care (New Rochelle)*. 2018; 7(4): 105–13. <https://doi.org/10.1089/wound.2017.0770>

Case study 1: leg ulcers

Beata Mrozikiewicz-Rakowska, Associate Professor, Department of Diabetology and Internal Diseases, Medical University of Warsaw, Poland. **Izabela Kuberka**, Diploma Nurse, Department of Nervous System Diseases, Wrocław Medical University, Poland. **Leszek Czupryniak**, Professor, Department of Diabetology and Internal Diseases, Medical University of Warsaw, Poland

A 74-year-old woman with visible spreading necrotic lesions on the gaiter region of both lower limbs was referred to an outpatient wound care clinic. She had a complex medical history with a 17-year history of hypertension and a 10-year history of type 2 diabetes mellitus and chronic obstructive pulmonary disease (COPD). The hypertension and diabetes were well controlled (average blood glucose levels: 115–140 mg/dl), although she had recently had an infectious exacerbation of the COPD. Box 1 lists the medications given for these comorbidities.

The patient had been diagnosed with non-Hodgkin's lymphoma stage IIIB (diffuse large B-cell lymphoma (DLBCL)) 2 months before the referral. Nuclear magnetic resonance spectroscopy (NMR) showed neoplastic infiltration, which partially covered the spinal canal in the lumbar section, causing compression of the spine and nerve roots. This had resulted in balance disorders and muscular weakness of the lower limbs, with the patient being periodically confined to a wheelchair. It had been decided to initiate treatment with chemotherapy (R-CHOP).

After the first cycle of chemotherapy, the patient developed lymphoedema, which was most pronounced in the lower left leg, with a bilateral swelling in the lower extremity up to the thigh. The lymphoedema was characterised by watery oedema and changes in tissue texture. Stemmer's sign was positive. Haemosiderin staining was mainly present, suggesting the presence of phlebotymphoedema.

Despite the patient's poor appetite, her total protein and albumin levels were not below the normal range. Likewise, no deterioration in the kidney's filtration function was found.

Due to the oedema, it was difficult to assess the pulse physically, but the skin temperature, measured by infrared thermometer, was within normal values. It was also difficult to assess the patient's ankle brachial pressure index (ABPI), although a two-phase pulse wave was present, which is indicative of insufficient perfusion to the lower limb. Doppler evaluation showed there were no haemodynamically relevant changes in the lower limb arteries.

According to the oncologist, the patient spent most of the day sat in her wheelchair. Unfortunately, the skin on

Box 1. Case study 1: patient comorbidities and their treatments

Comorbidity	Treatment
Hypertension	Ramipril: 1x5 mg Bisoprolol: 1x5 mg Torsemide: 1x5 mg
Chronic obstructive pulmonary disease	Formoterol: 1x12 ug/dose
Type 2 diabetes mellitus	Oral metformin: 3x850 mg

her legs rubbed against the frame, causing secondary cellulitis. This resulted in deep wounds with well-defined but uneven edges. The patient complained of severe pain in the lower limbs (9 out of 10 on a visual analogue scale (VAS)), for which 25 mg fentanyl patches were applied. The patient did not have a fever; laboratory tests revealed a slight increase in C-reactive protein (CRP).

Before the patient presented at the wound care clinic, her GP had attempted to treat the ulcers with an aerosol containing silver ions and another aerosol with neomycine, but these had no effect.

Fig 1 shows the wounds at presentation at the wound clinic. Here, assessment excluded systemic infection, although the wound was producing a large volume of exudate, which is an indicator of local infection. The wound cultures showed no growth of bacterial colonies. The most likely reason for this is that the prescription of trimethoprim/sulfamethoxazole for the COPD exacerbation could have contributed to the negative wound culture results, despite the clinical signs of wound infection.

The oncologist, vascular surgeon, diabetologist, dermatologist and wound-care nurse discussed the possible wound aetiology. Taking into consideration the sequential occurrence of skin rash, dryness, hyperpigmentation, lymphoedema, cellulitis and necrosis, the specialists realised that the primary cause of the lesion was skin toxicity due to chemotherapy. After joint analysis, it was decided to implement the Wound Hygiene concept, with the primary goal being to eliminate the wound biofilm and avoid infection.

Implementation of Wound Hygiene

In step 1, the periwound skin of the entire limb was cleansed with an irrigation solution containing betaine and PHMB (Prontosan, B Braun) to remove any dead tissue and disinfect the area. This enabled the lesions to be easily demarcated (Fig 2).

In step 2, the demarcated tissues were surgically removed with a scalpel and a surgical spoon. The thicker layers of necrosis attached to the bottom of the wound were also

debrided with an amorphous gel (GranuGel, ConvaTec) designed to dissolve and separate tissues. Fig 3 shows the wound following debridement. These procedures were repeated three times weekly for the first three weeks, and then once weekly thereafter.

In step 3, the wound edges were refashioned with wound pads (Wound Pad, Schülke) and the necrotic edges were removed with a scalpel. Next, due to their tendency to bleed, an ozonated olive oil preparation (Ozonella, Onkomed) was applied (Fig 4).

In step 4, the wound care nurse applied Aquacel Ag+ Extra dressing (ConvaTec) twice weekly to the mechanically cleansed and debrided wound surfaces to manage the exudate and lower the wound bioburden. This was covered with a light two-layer, long-stretch compression bandaging system incorporating zinc (CoFlex TLC Zinc Light, Milliken Healthcare).

After 2 weeks, the skin began to regenerate. The swelling and exudate volume reduced. After 4 weeks, there was granulation tissue on the wound bed and the wound edges had shrunk. After 8 weeks, 50% of the necrotic tissue had disappeared and the wound bed was granulating (Fig 5). The dressing regimen was stepped down to Aquacel Ag Extra (ConvaTec) and CoFlex TLC Zinc Plus Light. This combination was maintained until the wound was partially covered with epithelial tissue and the exudate reduced. After this, only CoFlex TLC Zinc Plus Light was applied until full healing occurred (month 4) (Fig 6). The patient remained pain free, in a good mental condition and was positive about the prospect of further oncology treatment.

The patient and wound were monitored by the wound-care nurse throughout the wound healing process, with periodical follow-up by the oncologist and surgeon.

In our clinical experience, the occurrence of hard-to-heal wounds in oncology patients is increasing. However, measures should be implemented to promote healing, despite the presence of neoplastic disease. In these patients, the wound aetiology should be assessed and wound care provided in consultation with, as a minimum, an oncologist, vascular surgeon and wound-care nurse.

This case study demonstrates the successful application of Wound Hygiene on a patient with cancer. In this case, the underlying lymphatic insufficiency, which was multifactorial (altered mobility, dependent limb position, altered calf-muscle pump, cancer burden, side effects of chemotherapy and periodical venous flow disorders), was the trigger for the ulceration and biofilm formation. Failing to address lymphoedema creates ideal conditions for bacterial growth. In the oncology setting, failure to implement effective wound care can increase the risk of complications, incurring extra costs and placing the patient at risk of harm. This case study indicates the potential benefits of training practitioners in different specialties on how to implement Wound Hygiene.

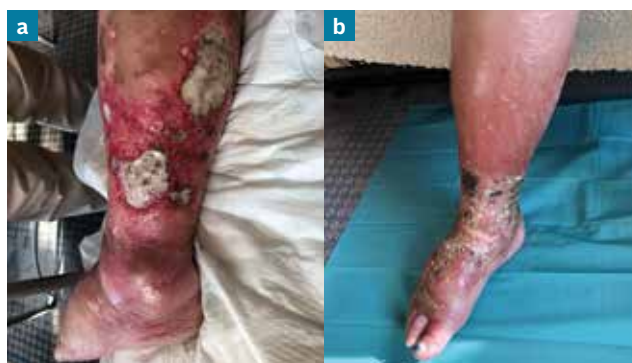

Fig 1. Case study 1: lymphoedema is present on the lower left limb: there is wet necrotic tissue and fibrin in the wound bed, which is covered with layers of biofilm (a); lymphoedema is present on the right lower limb: there is a skin rash and dead skin is peeling off (b)

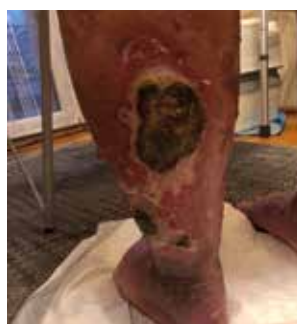

Fig 2. Case study 1: week 2, the left lower limb is prepared for debridement

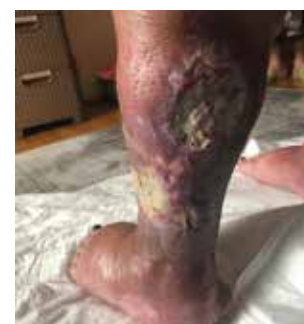

Fig 3. Case study 1: week 4, the left lower limb following debridement of necrotic tissue

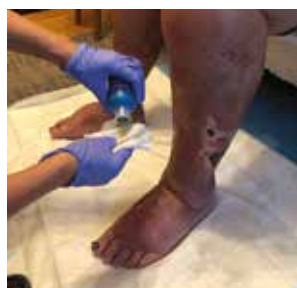

Fig 4. Case study 1: use of ozonated oil after refashioning the skin

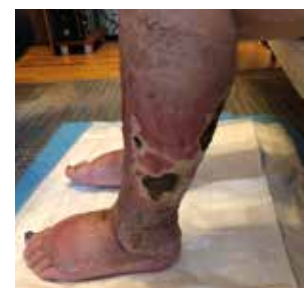

Fig 5. Case study 1: week 8, 50% is covered with granulating tissue

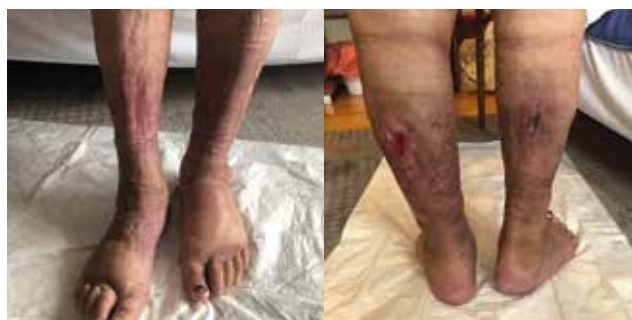

Fig 6. Case study 1: the wounds healed after 4 months

Case study 1: clinical summary

Clinical challenges at presentation	Deep painful wounds on the lower limbs in a patient with type 2 diabetes mellitus and cancer
Wound Hygiene protocol implemented	
Step 1: cleanse	Irrigation solution containing PHMB and betadine
Step 2: debride	Demarcated tissue with scalpel and surgical spoon. Thicker necrotic tissue with an amorphous gel
Step 3: refashion	Debridement pad
Step 4: dress	Aquacel Ag+ Extra dressing, plus two-layer compression bandaging system (weeks 1–8) Aquacel Ag Extra and compression (weeks 8–12) Compression only (weeks 12–16)
Outcome	Granulation tissue formation apparent from week 8 Necrotic tissue eradicated by week 12 Wound bed partially covered with epithelial tissue by week 12 Full healing occurred by 4 months

associated weight gain. Other patient comorbidities included hypertension and hypercholesterolaemia. Treatments given for these are listed in Box 2. The patient had also undergone a transurethral resection of bladder tumour (G3 bladder cancer) 8 months previously.

The patient had worn new poorly fitting shoes that resulted in bilateral superficial skin lesions around the first, fourth and fifth toes on the left foot and on the hallux of the right foot (Fig 7). During this period, despite being under the care of a primary care doctor, he was not instructed to wear offloading shoes. As a result, the ulceration spread to the external edge of the forefoot and to the deep tissues of the fifth toe (the focus of this case study). The patient was unable to detect this due to sensory neuropathy.

After 3 months, osteomyelitic changes necessitated resection of the fifth toe of the left foot. This occurred in the beginning of March 2020 when lockdown was announced. Due to the COVID-19 pandemic, the patient was unable to attend the surgical or diabetic foot outpatient clinics and so his wound management was temporarily managed by a GP nurse. Unfortunately, the postoperative wound did not heal. Moreover, a new ulcer developed on the plantar side of the foot, penetrating into the ligaments. Again, lack of offloading was one of the main reasons for the failure to heal. Wound management provided by the GP nurse involved use of topical antiseptics and periodic

Box 2. Case study 2: patient comorbidities and their treatments

Comorbidity	Treatment
Hypertension	Telmisartan: 1x80 mg Bisoprolol: 1x5 mg Torasemide: 1x5 mg
Hypercholesterolaemia	Rosuvastatin: 1x10 mg
Type 2 diabetes mellitus	Acarbose 50 mg td; metformin 850 mg td; insulin glargine 20 IU/day at night; insulin as part 6–8 IU td at meals, depending on glycaemic level

Case study 2: diabetic foot ulcer

Beata Mrozkiewicz-Rakowska Associate Professor, Department of Diabetology and Internal Diseases, Medical University of Warsaw, Poland. **Leszek Czupryniak**, Professor, Department of Nervous System Diseases, Wrocław Medical University, Poland

A 52-year-old obese man (body mass index (BMI): 38.8 kg/m²) with type 2 diabetes mellitus was referred to an outpatient wound care clinic with wounds of 5 months' duration on his feet.

The patient had diabetes mellitus for more than 20 years. Unfortunately, despite the use of intensive insulin therapy, along with metformin and acarbose, his glycaemic control was poorly controlled, as evidenced by an increase in HbA_{1c} level during the previous year (range: 9.3–11.7%). One reason for this was the lack of adequate patient education on implementation of fixed-dose insulin therapy, along with an

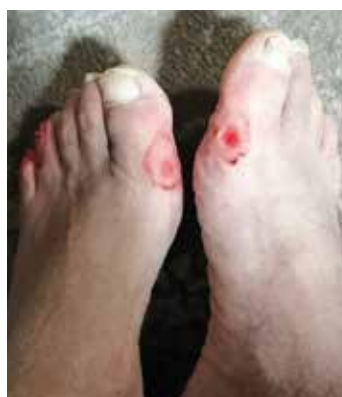

Fig 7. Case study 2: bilateral superficial skin lesions around the first, fourth and fifth toes on the left foot one month before his presentation at the diabetic foot outpatient clinic

dressing changes, mainly foam (Advasorb, Advancis), but not frequent debridement of locally infected tissue.

The patient was first seen in the diabetic foot outpatient clinic in May 2020. During the assessment, it was observed that, although a superficial area of erythema did not extend much beyond the wound edges, the wound itself penetrated down to the tendons and bones. A probe-to-bone test predicted osteomyelitis; X-ray images showed marginal osteolytic changes where the wound was extending down to the bone. It was not possible to perform a NMR test, as the radiological department was located in the area of the hospital in which patients with COVID-19 were treated.

The patient was not exhibiting clinical signs of systemic infection: he did not have a fever or chills, and his blood pressure reading and heart rate were within the normal range. Laboratory test results, including peripheral blood counts, inflammatory markers and kidney function, were within normal ranges, with the exception of an increase in erythrocyte sedimentation rate (ESR) count (73 mm/hr; reference range for male patients aged ≥ 50 years: 2–10 mm/hr), which is an indication of osteomyelitis.¹

There was a complete absence of touch and pressure sensation in the foot. Microbiological examination of a swab taken from the deep tissues, including bones, revealed mixed flora with common sensitivity to sulfamonomethoxazole. Peripheral arterial flow was assessed as preserved, based on an ABPI result of 1.2 and triphasic laser Doppler results.

Due to the features of osteomyelitis, a 6-week course of targeted antibiotic therapy (sulfamonomethoxazole) was prescribed.

Fig 8 shows X-rays of the foot after completion of the course. The patient was instructed to use offloading shoes: initially, the Optima Diab boot (Molliter) with crutches and later WCS Light shoes (Darco). A total contact cast was not used due to the GP staff's lack of experience with this type of device and the distant location of the diabetic foot clinic (the patient's family had difficulty taking him there for regular visits). There were still clinical signs of wound infection—some slough and necrotic tissue and a large volume of exudate—as well as maceration of the periwound skin. The Wound Hygiene protocol was initiated.

Implementation of Wound Hygiene

In step 1, the wound and periwound skin were cleansed with polyhexanide-based antiseptics (Prontosan, B Braun) to remove dead tissue and biofilm. This was important due to the recent treatment and surgery for bladder cancer, which increases the risk of Gram-negative infection.²

In step 2, the wound was debrided with a small surgical spoon, which was selected because of the uneven surfaces on the wound.

In step 3, the hyperkeratotic wound edges were removed with a scalpel to help facilitate the movement of cells from the wound bed. Due to their tendency to dry out, a

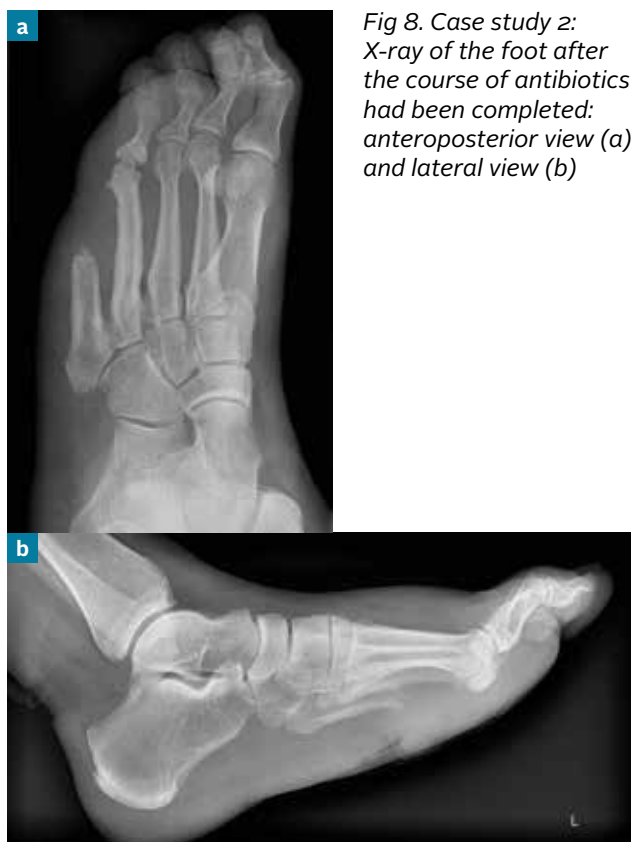

Fig 8. Case study 2: X-ray of the foot after the course of antibiotics had been completed: anteroposterior view (a) and lateral view (b)

cholesterol ointment containing vitamin A, solid and liquid paraffin and white petroleum jelly was also applied around the wound perimeter on the surrounding skin.

In step 4, Aquacel Ag+ Extra dressing was applied to prevent the biofilm reformation.

The Wound Hygiene regimen was performed at each dressing change. After one week, as there was no reduction in wound size and the exudate volume was still high, negative pressure wound therapy (NPWT) was applied. The NPWT was continued until week 4, as part of the Wound Hygiene protocol. To eliminate long journeys to the diabetic foot clinic, Wound Hygiene was performed by the GP nurse who was educated via telemedicine on how to perform it.

Throughout the follow-up period, Wound Hygiene was performed by the wound-care nurse, the diabetologist or the GP-nurse, depending on availability. After each episode of Wound Hygiene, the wound tended to reduce in size, the exudate volume to decrease, the wound edges to contract and granulation tissue to form. Unfortunately, the patient repeatedly tried to re-use his traditional footwear. He also was not fully adherent to his medication for his diabetes, nor following advice did he lose weight. This all combined to impair wound healing.

Furthermore, due to the pandemic, there were some long intervals between follow-up visits. As a result, the patient experienced two recurrences of local wound infection.

When these occurred, he presented at the diabetic foot clinic, which implemented Wound Hygiene, with deep, sharp debridement, and application of Aquacel Ag+ Extra dressing. This avoided the need for antibiotics. After the clinical signs of local infection disappeared, the dressing was stepped down to Aquacel Extra. Figs 9–12 show the wounds from one month after the first implementation of the Wound Hygiene protocol, to month 8. Each figure is

taken after one of the four steps of the Wound Hygiene protocol. The ulcers finally healed after 12 months (Fig 13).

A key challenge for this patient was the fact that, due to the pandemic, he did not have access to a diabetic foot ulcer specialist in his immediate vicinity. It is of interest, therefore, that implementation of the Wound Hygiene strategy helped manage clinical signs of local infection when they occurred without the need for antibiotics.

This case study demonstrates the benefits of educating wound-care nurses, diabetologists and GP-nurses on how to implement Wound Hygiene, particularly given the high incidence and risk of complications associated with diabetic foot ulcers. This proved to be particularly important during the pandemic.³

1. Michail M, Jude E, Liaskos C et al. The performance of serum inflammatory markers for the diagnosis and follow-up of patients with osteomyelitis. *Int J Low Extrem Wounds*. 2013;12(2):94–9. <https://doi.org/10.1177/1534734613486152>
2. Mai G, Chen L, Ran L et al. Common core bacterial biomarkers of bladder cancer based on multiple datasets. *Biomed Res Int*. 2019; 4824909. <https://doi.org/10.1155/2019/4824909>
3. Casciato DJ, Yancovitz S, Thompson J et al. Diabetes-related major and minor amputation risk increased during the COVID-19 pandemic. *J Am Podiatr Med Assoc*. 2020; Nov 3: 20–224. <https://doi.org/10.7547/20-224>

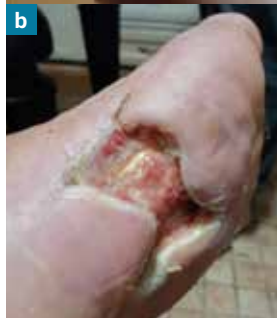
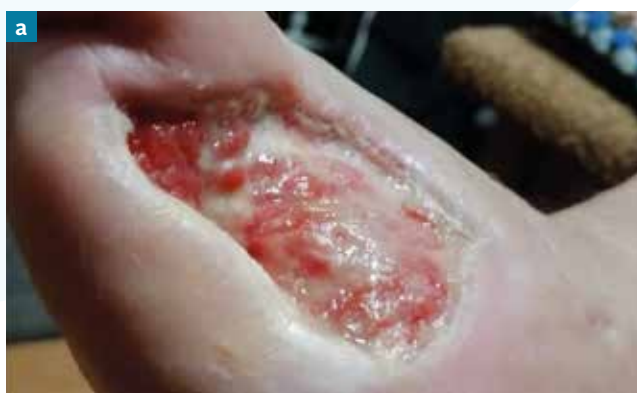
Fig 9. Case study 2: the wounds one month after the initial implementation of Wound Hygiene. There is a large swelling on the plantar side of the left foot and a thick layer of slough on the wound bed (a); the wound after resection of the fifth toe (lateral aspect) (b)

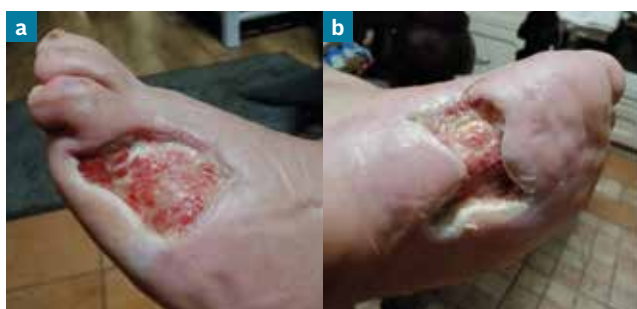

Fig 10. Case study 2: the wounds 3 months after the initial implementation of Wound Hygiene. Condition of the wound bed after debridement: plantar aspect (a); lateral aspect (b)

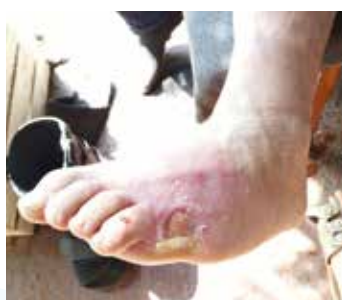

Fig 11. Case study 2: the wounds 5 months after the initial implementation of Wound Hygiene: removal of the hyperkeratotic wound edges

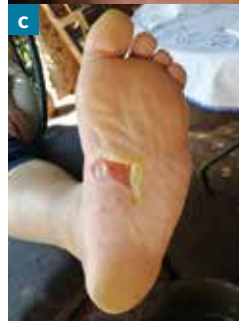
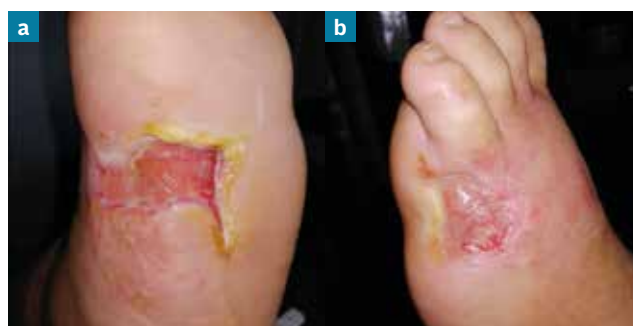
Fig 12. Case study 2: the wounds 8 months after the initial implementation of Wound Hygiene: before application of the cholesterol ointment (plantar aspect) (a); effects of skin care (cholesterol ointment) on the wound edges (dorsal) (b) and plantar regions (c)

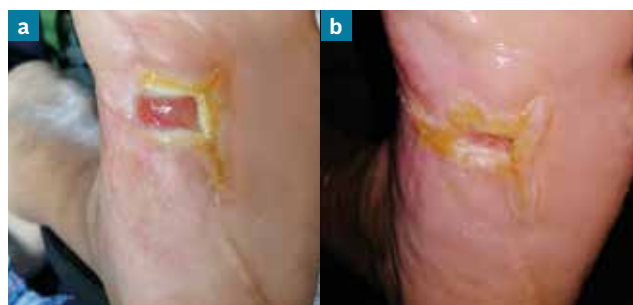

Fig 13. Case study 2: the plantar wound continued to heal (a); the wound at 12 months, where 90% epithelialisation has occurred (b)

Case study 2: clinical summary

Clinical challenges at presentation	Neuropathic foot ulcer in patient extending down to bone and tendon. Provision of care hindered by lockdown restrictions and patient non-adherence to offloading
Wound Hygiene protocol implemented*	
Step 1: cleanse	PHMB irrigation solution
Step 2: debride	Uneven wound surface with surgical spoon Deep sharp debridement during two episodes of local infection
Step 3: refashion	Hyperkeratotic wound edges removed with scalpel
Step 4: dress	Aquacel Ag+ Extra dressing (weeks 4–24) Aquacel (weeks 24–32)
Outcome	Full healing occurred in 12 months. Need for antibiotic avoided

* Negative pressure wound therapy was applied between weeks 2–4

Case study 3: infected insect bite

Paz Beaskoetxea Gómez, Head Nurse, Wound Unit, OSI Barrualde, and **Melina Vega de Ceniga**, Angiologist and Vascular Surgeon, Wound Unit, OSI Barrualde and Department of Angiology and Vascular Surgery, Hospital de Galdakao-Usansolo, Bizkaia, Spain

A 45-year-old man, with no relevant medical history, was bitten by an unidentified insect on the dorsum of his right hand (Fig 14a). Three days later, he developed local inflammation, purulent discharge and fever. He was started on amoxicillin-clavulanic acid 875/125 mg/8 hours and the fever disappeared. However, the cellulitis in his hand progressed up his forearm to his elbow. The ulcer was now 3 x 2 cm and had active purulent discharge and devitalised edges (Fig 14b). The patient's C-reactive protein levels were 156.63 mg/l (normal value: 0–5 mg/l), his procalcitonin level (indicator of the severity of bacterial infection) was 0.1 ng/ml (normal values: 0–0.5 ng/ml) and his leucocyte count was 13090 (80% neutrophils).

Bacteriological culture of the debrided tissue was positive for *Staphylococcus aureus* sensitive to cloxacillin,

erythromycin and clindamycin, but resistant to penicillin and ciprofloxacin. Treatment with amoxicillin-clavulanic acid, as described above, was maintained for 10 days.

The lesion was surgically debrided to remove the necrotic core and surrounding devitalised tissue. The underlying tendons, bones and joints were not affected. The residual ulcer was 3 x 3 cm wide and 1.5 cm deep, with sharp, mildly inflamed edges ('cliffs') and a vital wound bed (Fig 15). Because of the delicate location of the wound and the very small amount of viable tissue covering the dorsum tendons, the aim was to stimulate rapid granulation tissue formation.

Local treatment with negative pressure wound therapy (NPWT) was initiated 24 hours after the surgical debridement. After this, the patient was discharged and invited to attend the outpatient wound care clinic for weekly follow-up visits.

Implementation of Wound Hygiene

As biofilm was not considered to be a barrier to healing in this case, Wound Hygiene was implemented with the aim of improving granulation tissue formation. Based on the characteristics of this insect bite, post-surgical debridement, it was initially considered that this would be more effectively achieved with NPWT, as opposed to a topical dressing, for step 4.

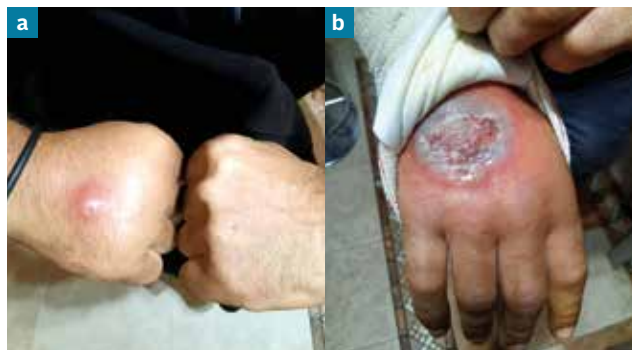

Fig 14. Case study 3: the initial insect bite (a) and with signs of cellulitis 3 days later (b)

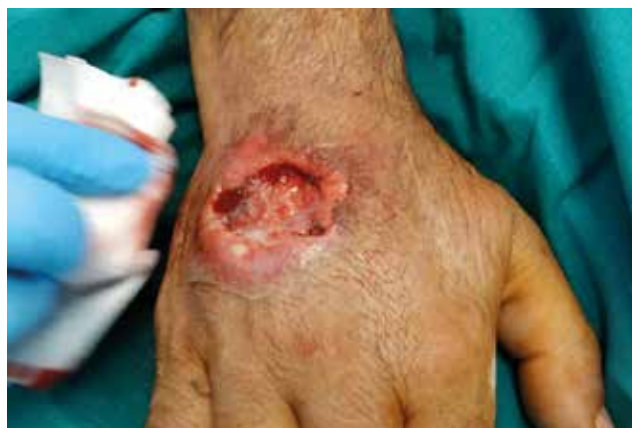

Fig 15. Case study 3: the wound following surgical debridement

In step 1, the wound was cleansed with saline and a chlorhexidine sponge.

In step 2, limited mechanical sharp debridement was performed.

In step 3, the wound edges were refashioned with the same blade, and both the edges and the wound bed were cleansed with 0.5% chlorhexidine solution.

In step 4, the patient was supplied with a disposable NPWT system (Avelle NPWT system, ConvaTec). Avelle dressings were applied, which were attached to a single-use pump that provided 80 mmHg continuous negative pressure (Fig 16a). It was considered that NPWT would help promote healing of this surgical wound.

The Wound Hygiene protocol took 8–10 minutes to complete. It was well tolerated by the patient, with no need for local anaesthetics.

The wound progressed quickly: a significant reduction in its width and depth was observed after only 14 days, along with granulation tissue formation (Fig 16b). The wound now measured 2 x 2.3 cm and was only 1 mm deep. The edges were soft, as opposed to the initial 'cliffs', with no residual inflammation.

Once a firm, granulating wound bed was achieved (on approximately day 14), the NPWT was replaced with Aquacel Ag+ Extra as the primary dressing and Aquacel Foam (ConvaTec) as the secondary one (step 4). The aim was to avoid complications and prevent biofilm formation.

Post use of the disposable NPWT system, at week 3, the dressings were changed twice weekly, during which time Wound Hygiene was implemented. Fig 17a shows the wound at the end of this week. From the fourth week, Wound Hygiene was performed once weekly. In the fifth week, the dressing regimen was stepped down to the silicone Hydrofiber (Aquacel Foam) only (Fig 17b).

Complete ulcer healing was achieved 6 weeks after the initial insect bite (Fig 17c).

Different approaches to the treatment of this wound could have been adopted. In this case, given the wound location and the initial fast deterioration, the priority was to stimulate fast granulation tissue formation. Any involvement of the wound with the tendon apparatus of the hand could have caused functional sequelae. We also tried to facilitate quick and safe referral to an outpatient setting, enhancing the patient's quality of life while ensuring specialist wound care. This is why, immediately after surgical debridement, NPWT was administered and early discharge sought. Once a firm, granulating wound bed was secured, a more standard moist wound care regimen was applied until full healing, with good outcome and no functional sequelae.

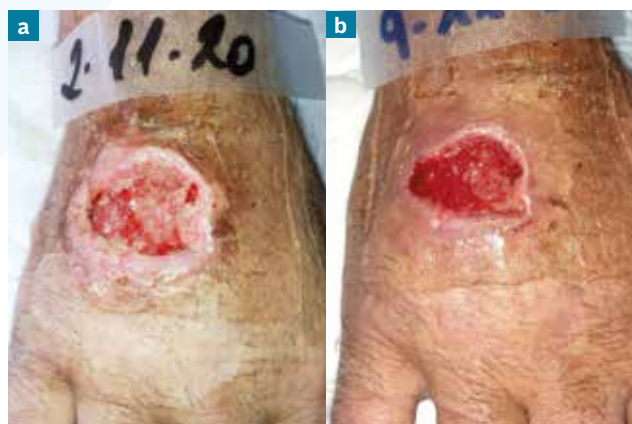

Fig 16. Case study 3: the wound following cleansing, debridement and refashioning of the edges, after one week of treatment with portable negative pressure wound therapy (NPWT) (a) and after 14 days of steps 1–3 of the Wound Hygiene protocol plus NPWT (b)

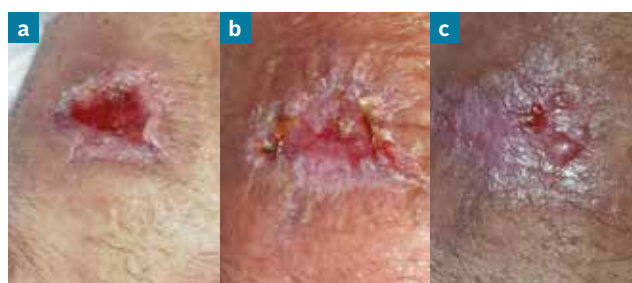

Fig 17. Case study 3: the wound after the first week of implementation of all four steps of the Wound Hygiene protocol with application of Aquacel Ag+ Extra dressing without NPWT (a); after 5 weeks of Wound Hygiene, when the dressing regimen was stepped down to a silicone foam only (b); full healing occurred 6 weeks after the initial insect bite (c)

Case study 3: clinical summary

Clinical challenges at presentation	Cellulitis resulting from an insect bite
Wound Hygiene protocol implemented*	
Step 1: cleanse	Saline and chlorhexidine sponge
Step 2: debride	Sharp (blade)
Step 3: refashion	Blade
Step 4: dress	Portable NPWT (weeks 1-2) Aquacel Ag+ Extra dressing and Aquacel Foam (weeks 2-3) Aquacel Foam (weeks 3-6)
Outcome	Full healing occurred within 6 weeks
* Follows antibiotic therapy and surgical debridement	

Case study 4: surgical wound – diabetic foot stump

Melina Vega de Ceniga, Angiologist and Vascular Surgeon, Wound Unit, OSI Barrualde and Department of Angiology and Vascular Surgery, Hospital de Galdakao-Usansolo, and **Paz Beaskoetxea Gómez**, Head Nurse, Wound Unit, OSI Barrualde, Bizkaia, Spain

A 62-year-old man was admitted to hospital with a painful septic diabetic ulcer on his right foot. The patient had a history of type 2 diabetes mellitus, hypertension, dyslipidemia, morbid obesity, mild ventricle dysfunction, atrial fibrillation, sleep apnoea syndrome and chronic renal failure requiring haemodialysis.

Dry necrosis was present on the fourth toe on the foot, with extensive humid gangrene of the distal and mid-plantar surface, but the dorsum was unaffected (Fig 18). There were extensive signs of chronic venous disease, with oedema and skin pigmentation, but no palpable varicose veins. His femoral pulses were palpable, but the popliteal and distal pulses were absent bilaterally.

Due to extensive calcification, the patient's ankle brachial pressure index (ABPI) was inconclusive, but the pulse-volume recording curves were good down to the ankle. Computer tomography (CT) angiography showed severe and extensive calcification of the femoropopliteal and tibial vessels in both lower limbs. A complementary MRI showed patency of the three tibial vessels down to the foot, with several areas of significant stenosis in the distal anterior tibial artery, but good flow and no significant disease of the peroneal and posterior tibial arteries; the arch was also patent. The ischaemic component was

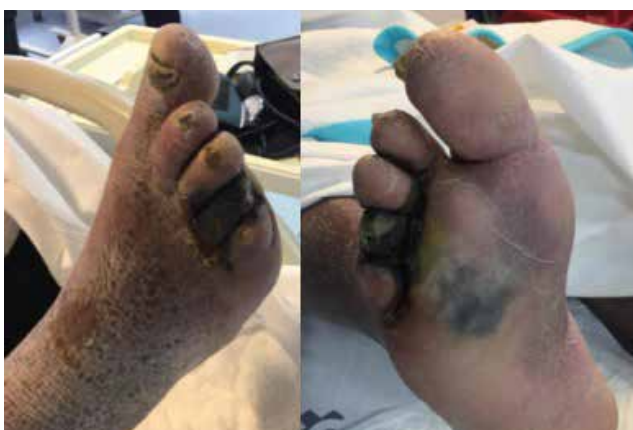

Fig 18. Case study 4: the septic diabetic foot ulcer at presentation

therefore considered mild and revascularisation was not deemed necessary. The predominant factors were neuropathy and acute infection. Venous ultrasound examination revealed mild deep venous reflux, a competent superficial venous system in the right lower limb and an incompetent great saphenous vein in the left lower limb.

On admission and under local anaesthesia, the patient underwent emergency open disarticulation (amputation) of his fourth toe and extensive surgical debridement of the putrid plantar forefoot. While waiting for the culture results, broad-spectrum empiric antibiotics were initiated (meropenem 500 mg/24 h intravenous (IV) and metronidazole 500 mg/12 h IV), which satisfactorily controlled the infection.

Implementation of Wound Hygiene

In step 1, the wound was cleansed daily with a chlorhexidine sponge

In step 2, extensive sharp debridement was undertaken.

In step 3, the wound edges were refashioned with a blade to eliminate debris, exudate, devitalised tissue and biofilm.

In step 4, post-debridement cleansing with 0.5% chlorhexidine solution was followed with application of Aquacel Ag+ Extra (primary dressing) and Aquacel Foam (secondary dressing). In addition, a zinc barrier cream (Conveen Critic Barrier, Coloplast) was used to protect the periwound skin from exudate.

The cultures were negative or non-conclusive (skin flora). The antibiotics were stopped after 7 days, as there was no exudate and no local inflammation. However, there was extensive dry necrosis on the plantar aspect up to the tarsus. Perfusion to the unaffected surrounding area was good. Once the acute infection had resolved, the next step was surgical reconstruction of the foot.

On the eighth day after admission, the patient underwent open transmetatarsal amputation of his right foot, with extensive debridement of all necrotic tissue and sectioning of the five metatarsals at their base, where there were no clinical signs of infection. The bone sections were covered with deep muscles. Negative pressure wound therapy (NPWT) (Renasys, Smith+Nephew) was administered to the open stump to stimulate and accelerate granulation formation on what was a very large wound bed (Fig 19a).

The NPWT was maintained for 5 weeks, with dressing changes taking place every 5–7 days. Steps 1–3 of the Wound Hygiene protocol were performed at every dressing change. This involved cleansing the open wound and foot up to the ankle with a chlorhexidine sponge, sharp debridement of the stump and refashioning of the edges with a blade, and post-debridement cleansing with 0.5% chlorhexidine solution. Following this, the NPWT sponge was reapplied (Renasys, Smith+Nephew) (Fig 19b).

By week 5, there was progressive formation of granulation tissue on the plantar area, but devitalised tissue on the dorsal edge of the wound, with partial exposure of the first to fourth metatarsal bone sections (Fig 19c). The objective of promoting granulation tissue formation on the plantar aspect had been achieved, but the dorsum

was not improving. NPWT was therefore stopped, but the team continued with the Wound Hygiene protocol as described above, implementing it twice weekly, replacing the NPWT with step 4 (Aquacel Ag+ Extra and Aquacel Foam as primary and secondary dressings, respectively) (Fig 20). The metatarsal diaphyses were remodelled with a surgical rongeur (a surgical instrument with a sharp-edged, scooped-shape tip) in the outpatient clinic.

During the first 3 months after presentation, the wound bed developed satisfactory granulation tissue over the remaining exposed bone (Fig 21).

Given the good progress with our wound-care regimen and the high risk that a skin graft would not take on this patient, given his comorbidities, we did not refer the patient for a plastic surgery consultation.

The Wound Hygiene protocol was delivered by specialist nurses in the wound unit for a further 6 months (Fig 22). With regards to step 4, in the last month (month 8), as the wound was clearly progressing towards healing, it was possible to step down and use Aquacel Foam only.

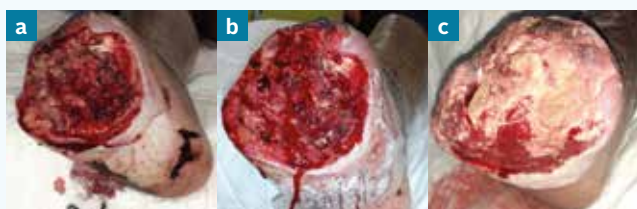

Fig 19. Case study 4: the open stump was started on negative pressure wound therapy on 20 March 2020 (a); the stump after cleansing, sharp debridement and refashioning of the edges (27 March) (b); granulation tissue developed on the plantar area but not the dorsal edge (22 April) (c)

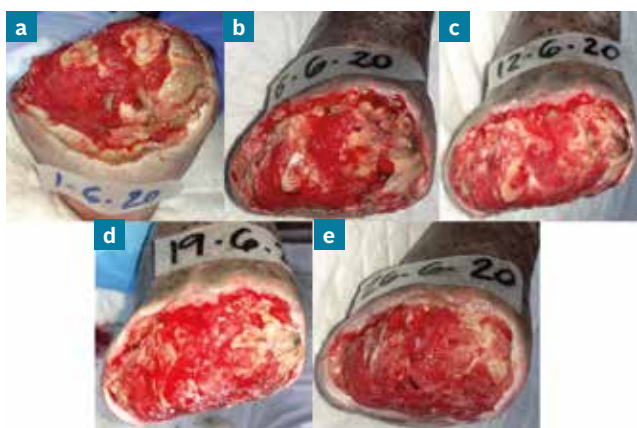


Fig 20. Case study 4: the stump following discontinuation of the negative pressure wound therapy and initiation of the four steps of the Wound Hygiene protocol 1 June (a); 6 June (b); 12 June (c); 19 June (d) 26 June (e)

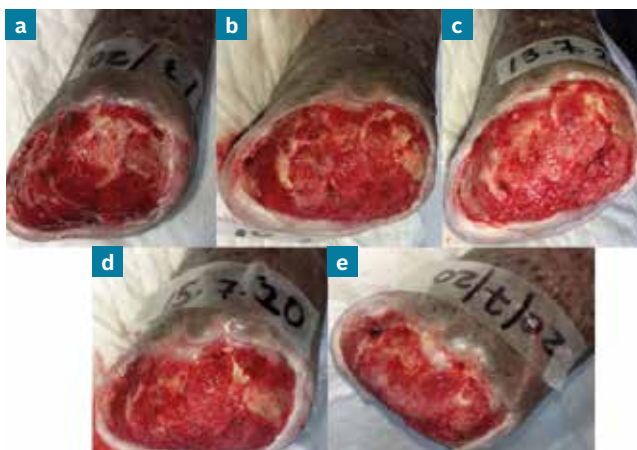


Fig 21. Case study 4: following remodelling of the metatarsal diaphyses, granulation tissue spread over the exposed bone: 1 July (a); 10 July (b); 13 July (c); 15 July (d); 20 July (e)

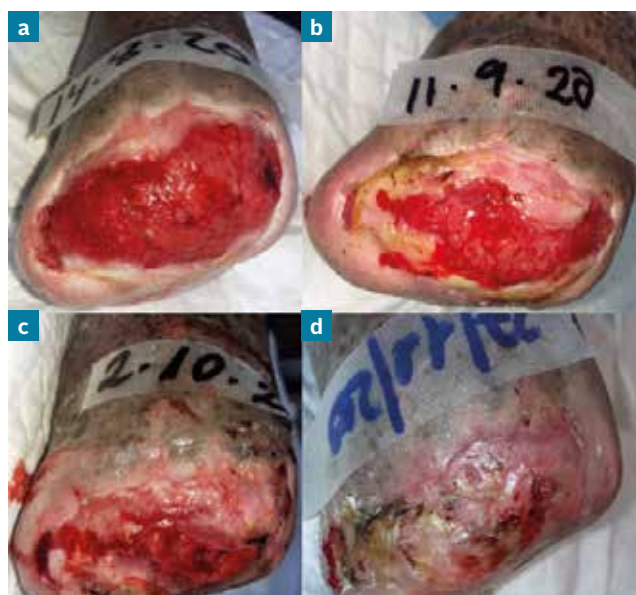


Fig 22. Case study 4: implementation of the Wound Hygiene protocol continued over the next 8 months: 14 August (a); 11 September (b); 2 October (c); 27 November (d)

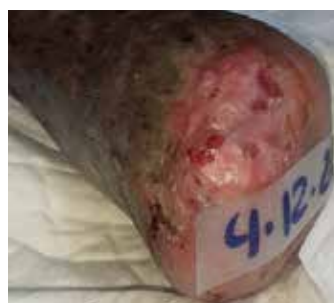

Fig 23. Case study 4: full healing over 9 months of treatment (4 December) with the Wound Hygiene protocol

With this strategy, we achieved progressive granulation and epithelialisation until complete healing occurred (9 months after the initial presentation) (Fig 23).

Case study 4: clinical summary	
Clinical challenges at presentation	Infected open stump following surgery for septic diabetic foot ulcer
Wound Hygiene protocol implemented*	
Step 1: cleanse	Chlorhexidine sponge
Step 2: debride	Sharp (blade)
Step 3: refashion	Blade
Step 4: dress	Aquacel Ag+ Extra dressing and Aquacel Foam (weeks 5–32) Aquacel Foam (weeks 32–36)
Outcome	Full healing was achieved in 9 months
* Surgical debridement of necrotic tissue and NPWT were performed on weeks 1–5	

Case study 5: non-healing traumatic wound

Angela Walker, Podiatry Lead Clinical Specialist, Birmingham Community Health Care NHS Foundation Trust

This case study describes a non-healing traumatic wound on the anterior right leg of a 61-year-old woman with type 2 diabetes mellitus and associated complications of peripheral neuropathy, nephropathy, retinopathy and obesity. The diabetes is well controlled with insulin (HbA1c: 55). The patient lives in a care home and is a cigarette smoker.

The wound was identified during one of the community podiatrist's regular visits to this patient in her care home, made due to these diabetes-related complications and the patient's long history of foot ulcerations. Examination of the feet revealed no problems, but the podiatrist expressed concern about a wound on the anterior right leg. According to the patient and her carers, it had been present for approximately 8 weeks, during which time there had been very little improvement, despite application of foam dressing 1–2 times weekly (Allevyn Gentle Border, Smith + Nephew).

The wound had occurred as a result of friction from a catheter bag and then a bump against the side of the

bed frame. The catheter was moved to the left leg, but the wound did not heal due to the underlying peripheral vascular disease, for which the patient had undergone an angioplasty nine months previously. What began as an acute traumatic wound was now considered a hard-to-heal wound due to its deterioration, duration and failure to progress towards healing.

The wound surface was shiny and sloughy, with an area of darker and stringy slough (Fig 24). The wound was producing a moderate volume of mildly malodorous exudate and its edges were red. The periwound skin showed signs of hyperaemia in response to tissue damage, as well as some irritation due to the excess exudate that had not been absorbed by the dressings. Given the lack of heat, strong malodour or excessive exudate, there was no concern about spreading infection, although a wound biofilm was suspected, due to the chronicity and the presence of slough and a shiny film. It is thought that biofilm is present in 60–100% of static non-healing wounds.¹

Implementation of Wound Hygiene

In step 1, the wound was cleansed with saline and gauze.

In step 2, the wound surface was debrided with a soft debridement pad (UCS Debridement, medi UK) to remove the biofilm, any unwanted tissue debris and slough.

In step 3, the wound edges and periwound skin were debrided with the same method as for step 2. A debridement pad was used as it was gentler than a scalpel for this patient, particularly at the wound edges, and could be used by any nurse involved in this patient's care.

In step 4, Aquacel Ag+ Extra dressing was selected as the primary dressing to prevent biofilm reformation and Aquacel Foam as a secondary dressing to retain the exudate and thus protect the periwound skin.

These four steps were performed at each of the twice weekly assessments and dressing changes by either the podiatrist or the community nursing team.

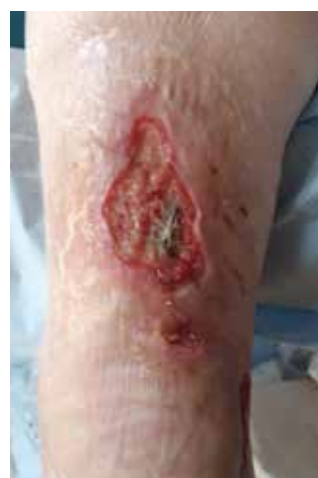

Fig 24. Case study 5: the wound at presentation

Case study 6: diabetic foot ulcers

Angela Walker, Podiatry Lead Clinical Specialist,
Birmingham Community Health Care NHS
Foundation Trust

A 62-year-old woman presented with three diabetic foot ulcers (DFUs), of up to 6 months' duration, on her right foot. She has type 2 diabetes mellitus, which is satisfactorily controlled (HbA1c: 54). Her medical history includes peripheral neuropathy and peripheral arterial disease. In the previous 2 years, an angioplasty had been performed in both lower limbs due to ischaemia, but the patient continued to experience diabetic foot ulceration and it was considered that no further vascular intervention would be successful. The patient is a cigarette smoker and has no interest in quitting.

Initially, the three DFUs had shown minor improvements, but following repeated infections they deteriorated to the point that urgent hospital admission for a possible below-knee amputation was required. Fortunately, one last attempt at an angioplasty was successful, improving blood flow to the leg and foot. To the patient's relief, this avoided the need for amputation.

However, there was still concern about the high level of strongly malodorous exudate, which was resulting in strikethrough. The patient had been prescribed numerous courses of antibiotics, which had made her feel unwell, so she was keen to avoid a further course, if possible.

The clinical notes indicated that, during the previous 6 months, the wounds had been cleansed during dressing changes and what were considered to be appropriate dressings had been applied. However, the treatment plan had not been adhered to, and often only dressings that were available in the patient's home were used. This needed to be rectified immediately.

At presentation, a thick greyish fibrin slough covered a significant portion of the wound bed, and a tendon was visible at the centre (Fig 27). The wound edges were rolled 'cliffs' and the periwound skin was macerated. Given the high exudate volume, malodour and presence of non-viable tissue on the wound bed, it was considered that a chronic local infection and biofilm were present. It was decided to prescribe a course of antibiotics (flucloxacillin 500 mg QDS for 14 days) and to implement Wound Hygiene.

Implementation of Wound Hygiene

In step 1, due to the local chronic infection and biofilm, both the wound and periwound skin were cleansed with an antibacterial solution (Prontosan, B Braun).

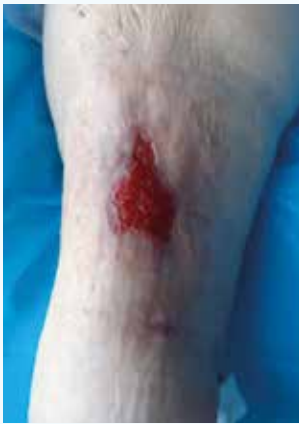

Fig 25. Case study 5: the wound at week 2

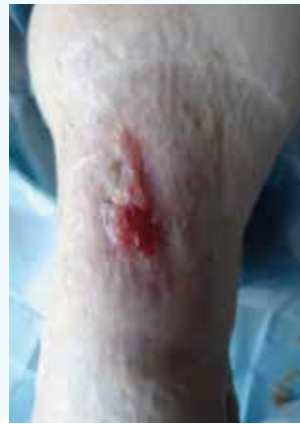

Fig 26. Case study 5: the wound at week 4

At week 2, the slough had disappeared and there was now 100% granulation tissue on the wound bed (Fig 25). The wound edges were shallower and contracting, and the periwound skin looked healthy. As the exudate volume had reduced to low, the wound was progressing towards healing and the dressing regimen was stepped down to just Aquacel Foam.

At week 4, the wound comprised 50% epithelial tissue, with some scar tissue formation (Fig 26). The exudate volume was still low.

Application of the Wound Hygiene protocol to this leg wound had rapid, positive results. This was particularly noteworthy given the patient's complex history, which included peripheral vascular disease. The wound had failed to progress for a number of weeks before implementation of the protocol. The patient was very satisfied with the outcome. Since week 4, the wound has continued to heal.

1. Bjarnsholt T, Eberlein T, Malone M, Schultz G. Management of wound biofilm Made Easy.

Case study 5: clinical summary

Clinical challenges at presentation	Non-healing traumatic wound in a patient with peripheral vascular disease
Wound Hygiene protocol implemented	
Step 1: cleanse	Saline and gauze
Step 2: debride	Soft debridement pad
Step 3: refashion	Soft debridement pad
Step 4: dress	Aquacel Ag+ Extra dressing and Aquacel Foam (week 1-2) Aquacel Foam (weeks 2-4)
Outcome	By four weeks, there was 50% epithelial tissue

In step 2, the wound surface was debrided with both a scalpel and a debridement pad (Debrisoft Pad, L&R) to remove loose debris and non-viable tissue and prepare the wound bed for healing.

In step 3, the debridement pad was used to debride the wound edges and cleanse the periwound skin.

In step 4, due to the clinical signs of potential infection and biofilm, Aquacel Ag+ Extra dressing was used as a primary dressing over both the wound surface and periwound skin. Aquacel Foam was the secondary dressing.

Wound Hygiene was implemented twice weekly by podiatry or the community nurses. No further antibiotics were prescribed.

At the next assessment, granulation tissue was observed, along with a reduction in slough and debris. The malodour had resolved after one dressing change. Improved vascular perfusion, along with good wound bed preparation, were aiding the progression towards healing.

By week 4, the wound was smaller and there was epithelial tissue in the middle of wound, with the rest predominantly comprising granulation tissue (Fig 28). The dressing regimen was stepped down to Aquacel Extra as the clinical signs of infection had resolved.

At week 8, the wound had continued to improve noticeably: the central area healed, leaving two smaller wounds (Fig 29). The exudate volume was still moderate, but the slough was less thick and dark.

Shared care with community nurses worked well, as they could easily follow the care plan and the four steps of Wound Hygiene. The only difference between the care provided by the podiatrist and the community nurses was that the podiatrist used sharp debridement and the community nurses soft debridement pads, with each working within their scope of practice.

Case study 6: clinical summary	
Clinical challenges at presentation	Three diabetic foot ulcers on the lower limb at risk of amputation
Wound Hygiene protocol implemented	
Step 1: cleanse	PHMB irrigation solution
Step 2: debride	Soft debridement pad (generalists) and scalpel (podiatrist)
Step 3: refashion	Soft debridement pad
Step 4: dress	Aquacel Ag+ Extra dressing and Aquacel Foam (weeks 1–4) Aquacel Extra (weeks 4–8)
Outcome	Malodour resolved after 1 dressing change. The central area healed in 8 weeks

The emotions for this patient ranged from initial apprehension and anxiety at the prospect of a limb amputation, to joy and relief at keeping the limb and watching the wounds progress toward healing, an outcome that had previously been inconceivable. The patient was impressed with such a positive outcome.

This is an example of how addressing the underlying issue—in this case, ischaemia—has a positive impact on wound healing. However, additional action is needed to progress hard-to-heal wounds towards healing. This case study describes how ongoing implementation of the Wound Hygiene protocol enabled good wound bed preparation. This not only facilitated wound closure, but also markedly improved the patient's quality of life.

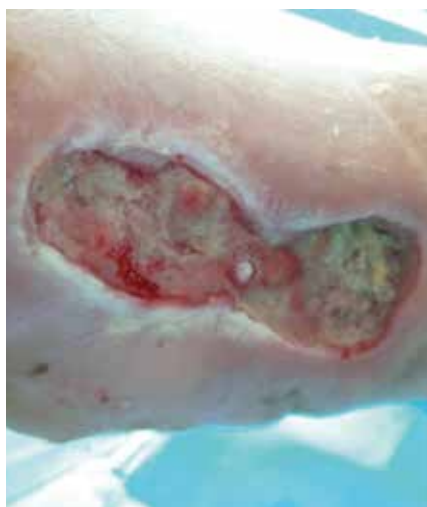

Fig 27. Case study 6: the wound on the medial aspect of the right foot

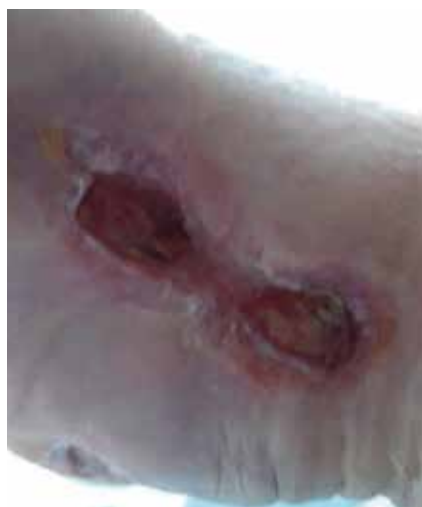

Fig 28. Case study 6: the wound at 4 weeks

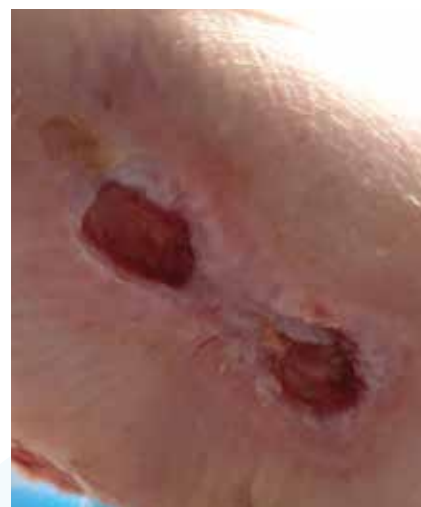

Fig 29. Case study 6: the wound at 8 weeks

Case study 7: hard-to-heal wound on the Achilles tendon

Annabelle Tomkins, Highly Specialist Podiatrist,
Birmingham Community Health Care NHS
Foundation Trust

A 74-year-old man presented at the community podiatry clinic with a hard-to-heal wound on his left Achilles tendon. He said that he had a recurring wound in that location after being bitten by a dog there approximately 40 years ago. The patient's medical history comprised coronary obstructive pulmonary disease (COPD), ischaemic heart disease (IHD) and peripheral oedema. Although there were times when the wound had healed in the past, in this instance he was fed up with how long it was taking to improve. The exact cause of this recurrence is unknown. Initially, the patient self-treated the wound, but when it failed to improve, he presented to a practice nurse (PN), after which he was referred to the district nurse (DN) and then the community podiatrist.

At the initial assessment by community podiatry, the wound was 12 weeks old. The wound bed measured 50 x 35 mm, and its bed comprised 40% stringy yellow-brown slough and 60% granulation tissue (Fig 30). The edges were rolled, with undermining; the distal edge was 12 mm deep. The patient's pulses were biphasic and regular, and his ankle brachial pressure index (ABPI) was 1.08. Although there were no clinical signs of infection, there was a faint malodour.

Implementation of Wound Hygiene

The community podiatry team instigated a Wound Hygiene regimen for this patient, to be implemented twice weekly: by the podiatrist at the patient's weekly community podiatry clinic follow-up visit and by district nurses (DNs) at the interim home visits.

In step 1, both the podiatrist and DNs cleansed the wound and periwound skin with a soft debridement wipe (UCS Debridement, Medi UK).

In step 2, the podiatrist sharp debrided the slough with a scalpel at each weekly podiatry appointment, when pinpoint bleeding would occur. Meanwhile, the DNs also debrided it with the soft debridement wipe at the home visits.

In step 3, both the podiatrist and DNs cleansed the wound and periwound edges with the soft debridement wipe to remove any remaining wound debris, reduce the wound bioburden and prevent biofilm formation. The wound edges were refashioned with a soft debridement wipe and

by lifting any dry periwound skin. The same method was used by both the podiatrist and DNs.

In step 4, as the wound was at risk of infection and due to its antibiofilm properties,¹ folded Aquacel Ag+ Extra dressing was packed into the wound, which was covered with Aquacel Foam Non-adhesive. An elasticated viscose stockinette (Clinifast (blueline), CliniSupplies), sub-bandage wadding (K-Soft, Urgo Medical) and a second layer of blueline Clinifast were applied over this. Finally, a removable soft cast boot (3M Softcast) was provided to offload and protect the wound, especially while the patient was in bed.

Due to the wound duration, the community podiatrist suspected that biofilm was present in the wound—approximately 80% of hard-to-heal wounds will have biofilm²—and so referred him to the secondary care podiatrist. She advised them to continue with the Wound Hygiene regimen. However, she also referred the patient to the plastic surgery team for their opinion, who advised that no other intervention was needed. The above treatment regimen, therefore, remained unchanged during this case study's 4-week follow-up period.

After 1 week of this treatment, the wound size reduced to 55 x 30 mm, and the wound bed comprised 10% slough and 90% granulation tissue. The undermining had reduced.

After 2 weeks, the wound size had reduced to 53 x 34 mm, and the wound bed was covered with 20% thin slough and 80% granulation tissue.

After 3 weeks, the wound measured 60 x 30 mm, with 10% slough and 90% granulation tissue. The wound margins were cleaner and there was no undermining. The wound bed was visibly shallower (Fig 31). Unfortunately, the patient had a fall between weeks 3 and 4, so was unable to attend the community podiatry clinic. Since then, the patient has continued to be seen by the DNs at home, with less frequent input from podiatry. However, the wound is improving.

Wound Hygiene is a simple process that can be easily incorporated into podiatry wound care and performed

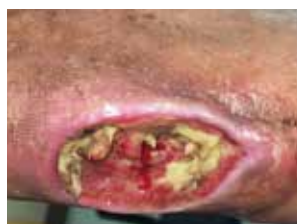

Fig 30. Case study 7: the wound after the initial implementation of Wound Hygiene at presentation: stringy slough and tendon is visible, along with cliff-like wound edges

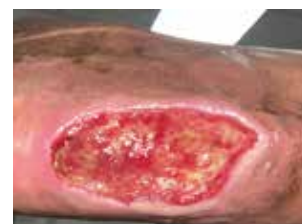

Fig 31. Case study 7: the wound at week 3. The slough has reduced and the wound bed is shallower

during domiciliary visits. For step 2, DNs can implement it by using soft debridement wipes instead of a blade. Supplementing holistic wound assessment with the Wound Hygiene protocol provides a great reminder of the importance of wound bed preparation in promoting healing.

1. Metcalf, D., Bowler, P. (2020). Clinical impact of an anti-biofilm Hydrofiber dressing in hard-to-heal wounds previously managed with traditional antimicrobial products and systemic antibiotics. *Burns Trauma*. 8 (0)
2. Edwards-Jones, V. (2018). Biofilm-based wound care: how to cleanse, debride and manage chronic wounds. *Wounds UK*. 14 (3), p10-16.

Case study 7: clinical summary	
Clinical challenges at presentation	Sloughy recurring on the Achilles tendon
Wound Hygiene protocol implemented	
Step 1: cleanse	Soft debridement wipe
Step 2: debride	Sharp (scalpel): podiatrist Debridement pad: district nurse
Step 3: refashion	Soft debridement wipe
Step 4: dress	Aquacel Ag+ Extra dressing and Aquacel Foam Non-adhesive
Outcome	Percentage of slough reduced from 40% to 10% in 3 weeks and the undermining disappeared

Case study 8: arterial leg ulcer

Angela Walker, Podiatry Lead Clinical Specialist, Birmingham Community Health Care NHS Foundation Trust

A 90-year-old woman presented with a wound on her left ankle that had deteriorated quickly after a knock against her walking frame. The patient, who lives alone, is mobile and quite independent in her ability to perform her daily activities. Although thin and frail, with very fragile skin, she was generally well and able.

The patient's medical history comprised heart problems (aortic stenosis and atrial fibrillation) and peripheral arterial disease. In the previous 3 years, angioplasty had been performed on both lower limbs and, in the past year, she had been treated for ischaemic ulcerations in the right forefoot and auto-amputation of some toes.

The patient was referred to the community podiatry clinic, where she said she had been self-managing the wound with basic sterile dressings and remarked how quickly it had deteriorated. She said it was 4 weeks old. At the assessment, the wound measured 58 x 55 mm (its depth was not visible) and was producing a moderate volume of exudate, which the dressings were unable to contain (Fig 32). The wound bed comprised 100% thick, adherent slough. The wound was also affecting the Achilles tendon, where a second wound, which was sloughy and moist, had developed. The patient said the wound was causing her discomfort.

Due to the patient's history of ischaemia, the fragile nature of her limb and skin, and the rapid deterioration of the wound, the podiatrist recognised that healing would potentially be difficult to achieve. Following assessment, the Wound Hygiene protocol was carefully implemented. Meanwhile, an urgent referral was also made to the vascular department, which proposed that vascular intervention was not appropriate at this stage.

Implementation of Wound Hygiene

In step 1, the wound was cleansed with an antibacterial solution (Prontosan, B Braun) or saline.

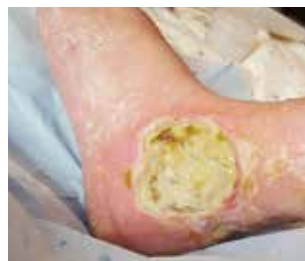

Fig 32. Case study 8: the wound at presentation

In step 2, the wound bed was debrided with a soft debridement pad (UCS Debridement, Medi UK) and tweezers. Initially, pain was an issue, so the patient was advised to take oral pain relief before each visit, and extra care was taken to cleanse and debride the wound without causing discomfort.

In step 3, the soft debridement pad was used to lightly debride (refashion) the wound edges and periwound skin.

In step 4, due to the wound's static nature and the presence of sloughy, shiny, slimy tissue, it was considered that a mature biofilm might be present in the wound. Aquacel Ag+ Extra dressing was applied as a primary dressing to help promote desloughing, remove cellular debris and prevent biofilm reformation. Aquacel Foam was used as a secondary dressing to absorb the exudate and protect the fragile periwound skin. Both dressings were changed twice weekly.

This dressing combination managed the exudate levels and the patient found the dressings comfortable. Finally, the patient was given an offloading cast to wear in bed. Wound Hygiene was implemented by podiatrist only.

At week 3, the wound had slightly decreased in size (56 x 53 mm) and there was some improvement in the wound bed: the amount of slough had decreased and there were signs of granulation tissue (Fig 33). This reflects the removal of unwanted non-viable tissue and cellular debris. The exudate level was still moderate. The periwound skin was fragile and calloused at the wound edges.

At week 8, there were discernible signs of healing (Fig 34). The wound had reduced in size and its base was granular; the edges were shallower. Pain levels had slowly improved. There was no change in implementation of the Wound Hygiene protocol during this time.

At week 8, the slough had resolved and exudate decreased, and so it was now possible to step down to Aquacel Foam as the primary dressing.

On a limb where the prospect of healing was doubtful due to poor tissue perfusion, ongoing implementation of Wound Hygiene not only helped improve the condition of the wound bed and periwound skin, but also encouraged the patient, who recognised that her wound was improving. Although the treatment was a little uncomfortable at times, she felt it was worth it for the excellent results achieved. The wound went on to heal completely. The patient and their family are extremely grateful for the provision of this care. The second wound, located near the Achilles tendon, also improved.

In my experience, use of Wound Hygiene is achieving improvements in wounds that would have been considered static and hard to heal. In this case, progression was achieved in a patient with poor circulation, about whom practitioners might have been less optimistic, and more accepting that healing might never take place. The Wound Hygiene concept is simple, and can be easily implemented by practitioners with either basic or advanced knowledge of wound care.

Case study 8: clinical summary	
Clinical challenges at presentation	Sloughy wound in a 90-year-old patient with frail skin and peripheral arterial disease
Wound Hygiene protocol implemented	
Step 1: cleanse	PHMB solution or saline
Step 2: debride	Soft debridement pad and tweezers
Step 3: refashion	Soft debridement pad
Step 4: dress	Aquacel Ag+ Extra and Aquacel Foam (weeks 1–8) Aquacel Foam (weeks 8–10)
Outcome	By week 8, there were discernible signs of healing

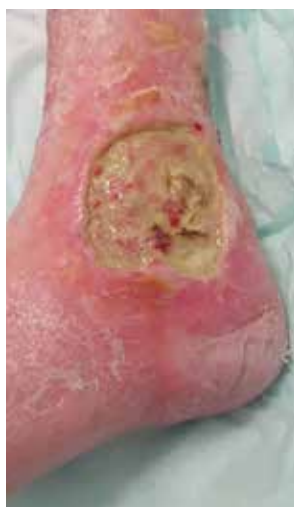

Fig 33. Case study 8: the wound at week 3

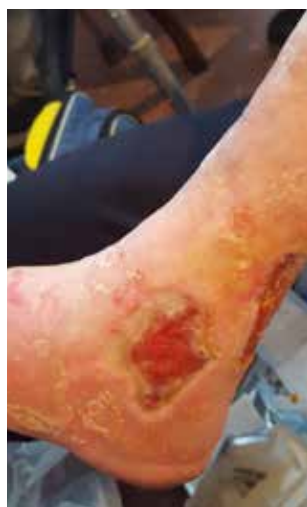

Fig 34. Case study 8: the wound at week 8

Case study 9: leg ulcer on a patient with diabetes

Jenny Hurlow Wound Specialised Nurse Practitioner, Advanced Wound Care, Southaven, Mississippi, US

A 46-year-old man with type 2 diabetes mellitus presented at a wound clinic in northern Mississippi with a left medial upper calf haematoma resulting from a motor vehicle accident that had happened 7 weeks previously (Fig 35a). Assessment revealed intact sensation and triphasic pedal pulses auscultated with hand-held Doppler. The patient was a non-smoker, his vital signs were within normal limits and he reported a blood glucose of 172. His medical records indicated that he had recently completed a 10-day course of oral antibiotics (sulfamethoxazole-trimethoprim (SMX-TMP)). However, his wound continued to exhibit extensive periwound erythema, warmth, oedema and induration.

Week 1: at presentation, the wound was deroofed (Fig 35b) to release malodorous clotted blood. The resulting wound measured 3.5 x 1.5 x 1 cm with 3–10 cm of circumferential undermining and 40% devitalised tissue adherent to the wound edge. Visible on the wound bed was fatty necrosis at 5 and 7 o'clock, as well as an opaque adherent wound bed film (Fig 35c). Normal saline and gauze sponge were used to cleanse and mechanically debride this wound, and then a Levine swab specimen was obtained from the wound bed for culture.

Implementation of Wound Hygiene

In step 1, after haematoma evacuation, a non-cytotoxic antiseptic wound cleanser (0.057% sodium hypochlorite) and gauze were used to cleanse the periwound skin.

In step 2, non-healing tissue was carefully debrided with a disposable curette to further limit the source of infection.

In step 3, residual devitalised and denuded wound edges were also debrided in this way, after which the wound was cleansed thoroughly with the antiseptic cleanser.

In step 4, Aquacel Ag Advantage dressing (ConvaTec) was placed over the wound and lightly packed inside the undermining to promote a good moisture balance and reduce the bacterial load (Fig 35d). This dressing was covered with an abdominal pad and secured with a conform cotton wrap and coban wrap.

The patient was educated on the link between blood glucose control and optimal immune function, as well as the role of the dressings used and the importance of the care plan.

Culture results were received 3 days later. Based on these, a 10-day course of antibiotics (Augmentin 875 mg) was prescribed.

Week 2: on return to the clinic, the wound measurement was 5.7 x 3.8 x 1 cm. There was less periwound erythema but ongoing undermining. Devitalised tissue was observed on the wound edge from 2–12 o'clock. The wound bed was granular but covered with a recurrent semi-opaque film (Fig 36). Following removal of the old dressing, the wound and periwound skin were cleansed with the antiseptic cleanser to remove any loose bacterial load. A sterile disposable curette was used to debride the visible wound bed and undermined areas to remove any residual clots and disrupt the biofilm. The wound edges were then sharply debrided to remove adherent devitalised tissue and biofilm. The wound was cleansed again with the non-cytotoxic antiseptic cleanser. The same dressing regimen was used as for day 1.

Week 3: at the next visit to the centre, the wound showed a healthier granular bed, but also evidence of new local infection. A new tunnel was noticed at the proximal wound bed connecting to a lateral knee abscess, from which dark clotted blood could be expressed (Fig 37).

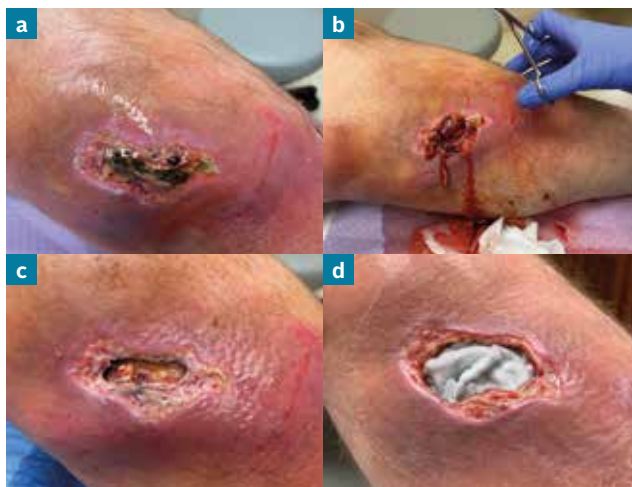

Fig 35. Case study 9: the wound on presentation at the clinic: week 1, day 1. At presentation (a); the wound was deroofed (b); fatty necrosis and an adherent film were visible on the wound bed (c); the wound was packed with the silver-impregnated Hydrofiber dressing (d)

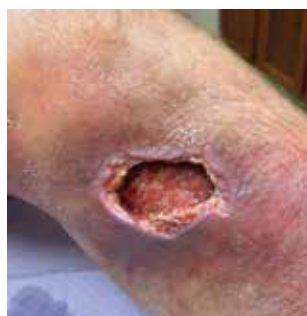

Fig 36. Case study 9: the wound on day 7. The periwound erythema has reduced but undermining is present

After the abscess content was expressed, the wound and periwound skin were cleansed as described above. A cotton-tip swab was used to mechanically debride the tunnel, after which the rest of the wound was carefully sharp debrided to disrupt the biofilm. The antiseptic cleanser was used to remove loosened infected, non-

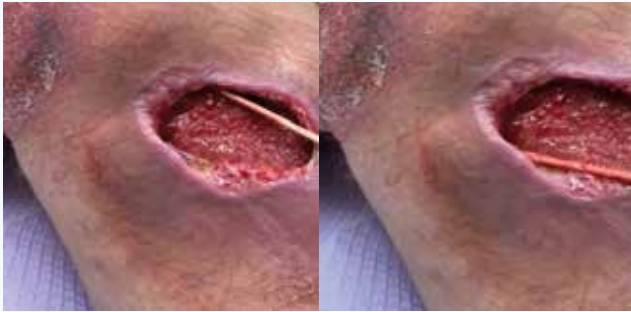

Fig 37. Case study 9: the wound on day 21. A new tunnel was observed on the proximal wound bed from which dark clotted blood was expressed

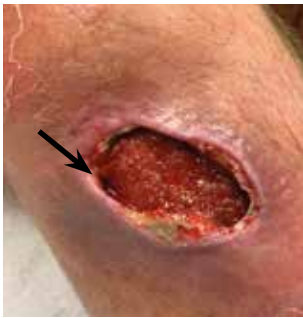

Fig 38. Case study 9: the wound on day 35. Inflammation on the periwound skin has reduced and there is evidence of healing at 11 o'clock

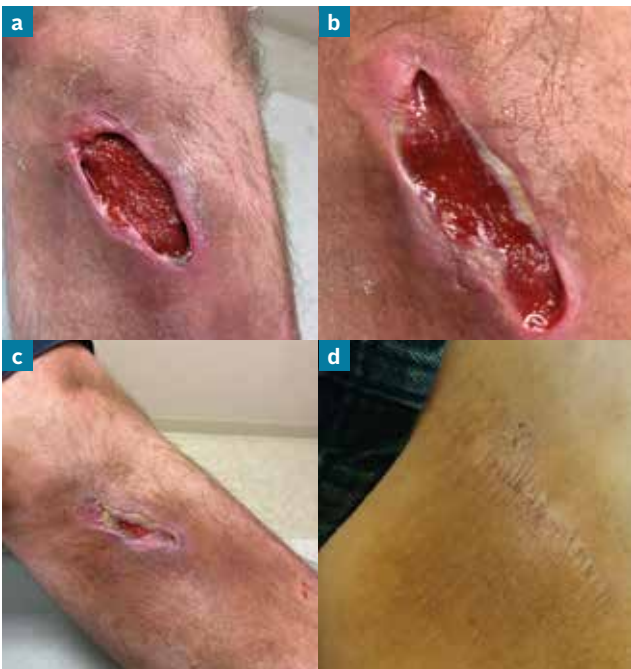

Fig 39. Case study 11: the wound from day 42 until full healing occurred 6 weeks later. Day 42 (a); day 49 (b); day 63 (c); day 77 (d)

healing tissue. The wound edges were sharply debrided to remove infected tissue and control the risk of epibole. Aquacel Ag Advantage Ribbon was carefully inserted through the tunnel into the small abscess. Aquacel Ag Advantage was placed over wound and lightly packed into the undermined areas and covered as described above. No antibiotics were prescribed.

Week 4: at the next visit (day 35 since clinic admission), there was decreased periwound skin inflammation, a healthy granular wound bed and evidence of healing at 11 o'clock (Fig 38).

The Wound Hygiene protocol of care continued with follow-up visits over the next 6 weeks until complete healing occurred (Fig 39a–d).

Initially, there was concern about the risk of recurrent infection in this diabetic wound, as well as interest in avoiding unnecessary antibiotic usage. Mississippi providers consistently write some of the highest number of antibiotic prescriptions in the US,¹ increasing the risk for development of antibiotic-resistant bacteria. However, in this patient, only one course of antibiotics was required after haematoma evacuation.

Subsequent systemic infection was avoided due to patient adherence to self-care, as well as the Wound Hygiene protocol of care, which included the use of an antimicrobial dressing that supports optimal exudate management and contains agents designed to penetrate and disrupt the protective biofilm phenotype.

¹ Centers for Disease Control and Prevention. Antibiotic prescribing and use in doctor's offices. Outpatient antibiotics: United States, 2018. <https://tinyurl.com/gh93cnwn> (accessed 01 May 2021)

Case study 9: clinical summary

Clinical challenges at presentation	Haematoma on upper calf with signs of systemic infection
Wound Hygiene protocol implemented	
Step 1: cleanse	Antiseptic cleanser and gauze
Step 2: debride	Curette
Step 3: refashion	Curette (day 0) Sharp debridement (weeks 1–11)
Step 4: dress	Aquacel Ag Advantage
Outcome	Full healing occurred on week 11

Case study 10: neuropathic diabetic foot ulcer

Raymond Abdo, Podiatrist, St Louis Foot and Ankle, St Louis, Missouri, US

This case study is about a 52-year-old man with a medical history of significant degenerative joint disease, past surgical procedures in both knees and peripheral neuropathy of unknown origin that resulted in occasional wounds in his feet. He is one of the first patients in our podiatry office to be treated with the Wound Hygiene concept.

The patient presented at the podiatry office with an ulcer on the plantar aspect of his right hallux. He had developed a significant blister in the area while camping, but was initially unaware of it due to the lack of sensation in the foot. He attended an urgent care centre, which prescribed an antibiotic cream. At a follow-up visit to his primary care provider, oral antibiotics were prescribed, but the wound failed to improve. He did not wear an offloading controlled ankle motion (CAM) during this period.

By the time the patient presented at the podiatry office, the wound was 2–3 weeks old. Vascular examination of his right lower extremity was unremarkable, with a Semmes Weinstein 5.07 monofilament test indicating a limited neurological protective threshold. The texture, turgor and temperature of the right extremity were all within normal limits, with no signs of cellulitis. The wound was assessed as a neuropathic foot ulcer.

The ulcer measured 4.9 x 3.7 x 0.2 cm. The wound bed was pale with minimal fibrous tissue, with no probe to bone or tendon. The wound edges were hyperkeratotic and there was mild callus (Fig 40). The wound was producing a moderate volume of serosanguineous drainage. Cultures were obtained and non-contact real-time fluorescence wound imaging for bacteria was performed.

The wound was initially treated with povidone-iodine solution and covered with a dry gauze, and the patient was advised to wear an offloading CAM walking boot to avoid further pressure, friction or shear exacerbating the ulcer. The patient was able to continue working despite the wound, although the boot restricted his mobility and lifestyle.

At the next assessment, 1 week later, the wound size had reduced to 4.0 x 2.5 x 0.2 cm. The culture results were positive for *Enterococcus*, methicillin-resistant *Staphylococcus epidermidis* and *Peptostreptococcus*. Based on these results and the findings of the real-

time fluorescence imaging, which showed red/pink discoloration along some of the peripheral edges, oral antibiotics (Augmentin and Bactrim) were prescribed.

Implementation of Wound Hygiene

In step 1, the wound bed and periwound skin were cleansed with hypochlorous acid solution.

In step 2, the wound bed was sharp debrided to remove bacteria and debris.

In step 3, the calloused wound edges were refashioned with a scalpel. Due to the neuropathy, no anaesthesia was required. Bleeding was controlled with compression, along with nitrate sticks when required.

In step 4, Aquacel Ag Advantage dressing was applied to manage the wound bioburden. The patient was told to change the dressing daily at home to support continuation of the dressing plan. He was also advised to continue wearing the CAM walker boot to maintain offloading.

Due to the pandemic, the patient was unable to attend the podiatry office until 4 weeks later (week 5 since his presentation at the podiatry office). During this time, he continued to wear the CAM walker boot and antimicrobial dressing, which he applied daily on his own. Assessment at this visit showed that the wound had improved, reducing to 3 x 2 x 0.2 cm. The wound bed was filled with 100% granulation tissue. The wound edges were flattening, but mild callus was still present; the periwound skin was no longer red. It was considered that use of the antimicrobial

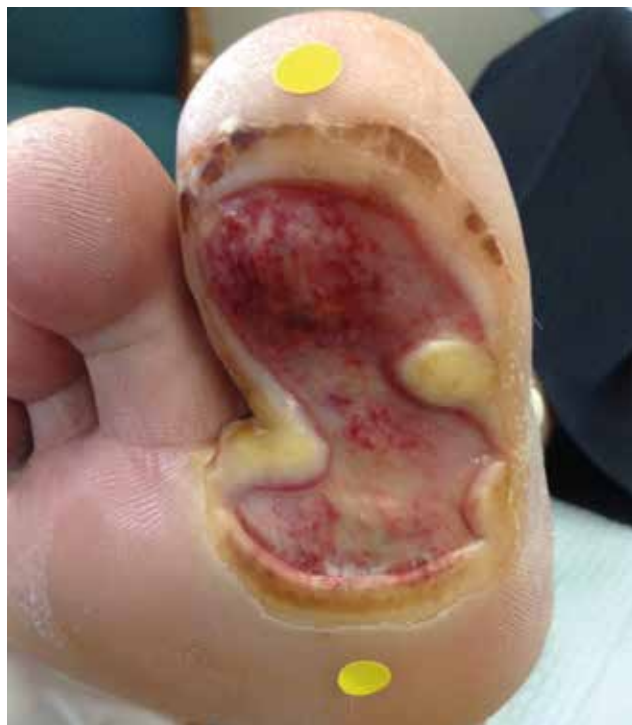

Fig 40. Case study 10: the wound on presentation at the podiatry centre

dressing had helped promote healing and avoid the need for more regular consultations, which would have been challenging in the pandemic.

Wound Hygiene was performed at this visit in the same way as described above. Aquacel Ag Advantage continued to be used for step 4, rather than a step down to a non-antimicrobial dressing, due to the need to continue the progression towards healing, given the patient's inconsistent visits to the podiatry office and the risk of biofilm reformation.

Because of the pandemic, the patient was unable to attend the podiatry office until 2 weeks later (week 7). In the meantime, he had continued to wear the CAM boot and the antimicrobial dressing, which he changed at home every 2–3 days, as required. The wound had decreased to 1.5 x 1.3 x 0.2 cm; the wound bed was still completely covered with granulation tissue, and the wound edges were flat, but still with some callus. Wound Hygiene was performed at the office visit, as described above.

The patient next attended the podiatry office on weeks 9 and 11, when the Wound Hygiene protocol was implemented, again as described above, although the dressing change frequency was reduced to every 3 days, as required. In between these visits, the patient continued to wear the CAM boot and the antimicrobial dressing. At week 11, the wound measured 1 x 0.5 x 0.1 cm. It still had 100% granulation tissue. The wound edges were mildly hyperkeratotic.

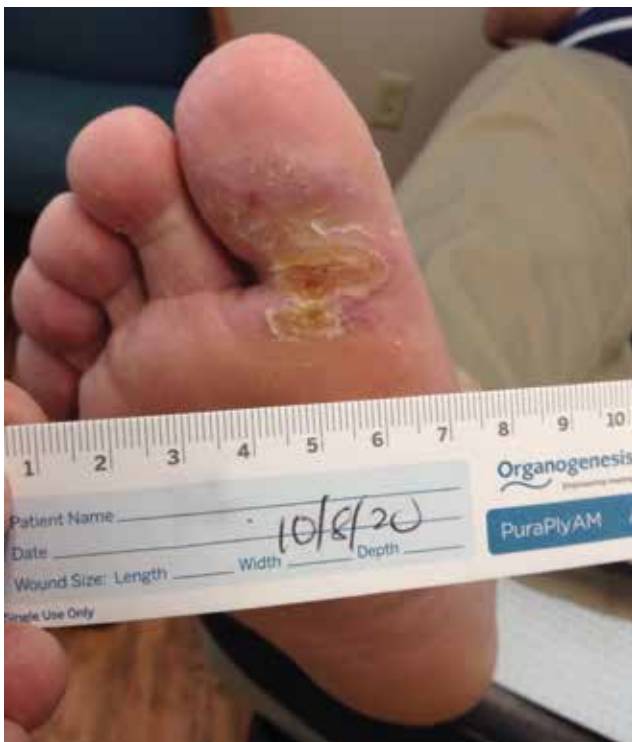

Fig 41. Case study 10: after 14 weeks of treatment, full healing occurred

On the patient's final visit to the office at week 14, the wound had closed (completely covered with epithelial tissue with no drainage) (Fig 41). Custom shoe inserts were ordered for him to prevent pressure points. As the patient no longer needed to wear the CAM boot, his mobility—and thus his quality of life—improved. The hallux continued to be monitored as the skin underwent remodelling.

Overall, a successful outcome was achieved for this patient, with this large wound progressing towards healing over the course of 14 weeks. The patient tolerated the Wound Hygiene protocol well and was extremely satisfied with the wound progression and outcome. We have since used Wound Hygiene successfully on other patients, and will continue to apply the protocol to hard-to-heal wounds encountered in our practice.

Case study 10: clinical summary

Clinical challenges at presentation	Large, infected, moderately exuding diabetic foot ulcer on the hallux
Wound Hygiene protocol implemented	
Step 1: cleanse	Hypochlorous acid solution
Step 2: debride	Sharp (scalpel)
Step 3: refashion	Scalpel
Step 4: dress	Aquacel Ag Advantage
Outcome	Full healing occurred in 14 weeks

Case study 11: surgical wound

Sara Sandroni Nurse Manager and **Elisa Marinelli** Nurse Specialist, both at Network Wound Care, Azienda USL Toscana Sud Est, Arezzo, Italy

A 72-year-old independent woman sustained a traumatic injury on her lower right limb at home. Her significant comorbidities were hyperuricaemia and hypercholesterolemia, which were both well controlled with medication. The patient presented at a hospital emergency room, where she was referred to the general surgical medical team for treatment. She returned home, but visited the emergency room every 5–7 days and had multiple short hospital admissions over the next 20 days. During this time, she remained under the care of the general surgical medical team.

On day 20, the patient was admitted to a general medical ward with gas gangrene of the soft tissues in the limb. Surgical debridement was performed, which evacuated some dense serous material. An incision of the thickened necrotic eschar was initially undertaken, followed by an excision of the affected area in the calf.

The resulting wound had well-vascularised tissue with evidence of granulation tissue. The patient was assessed by a specialist in infectious diseases and discharged with a wound-care regimen comprising cleansing with 0.9% sodium chloride and use of non-adherent dressings.

Following discharge, the patient had access to follow-up care from a specialist nurse, who worked in a team with the local general practitioner (GP) and their support team of home-care nurses. The wound was significantly reducing the patient's quality of life.

The patient was assessed by a specialist nurse. The wound bed was partly viable with islands of fibrin and areas of hypergranulation. There was also some slough, which extended to within 0.7 cm of the wound edges. The wound was producing a moderate amount of non-malodorous haemoserous exudate. The margins were jagged and ischaemic; 70% of their circumference (12–7 o'clock) were 'cliffs' and the remaining 30% 'beaches'. The periwound skin was red, brittle and oedematous (Fig 42). The patient's self-reported pain visual analogue score (VAS) was 5 out of 10.

Implementation of Wound Hygiene

The specialist nurse verbally explained the Wound Hygiene protocol to the patient, the GP and the local home-care nurses, after which it was implemented. The first few episodes of Wound Hygiene were performed by the specialist nurse, after which it was undertaken by the entire home-care nurses team.

In step 1, the wound was cleansed with PHMB solution (Prontosan, B Braun) for 15 minutes, as it had the characteristics of a hard-to-heal wound and the presence of biofilm was suspected.

In step 2, the wound was mechanically debrided with a debridement pad (Debrisoft, L&R). This was chosen because it could be performed in the home and was well tolerated by the patient. A hydrogel (Nu-Gel, Systagenix) was also used to promote debridement.

In step 3, the edges were stimulated with a curette without reaching pin-point bleeding. The curette, which was also used to remove the slough, was well tolerated by the patient.

In step 4, Aquacel Ag+ Extra dressing was applied to reduce the bioburden and prevent biofilm reformation. It was covered with a polyurethane foam (Biatain Non-adhesive, Coloplast).

The Wound Hygiene protocol was performed every 3 days (at dressing change) by either the home care nurses or the specialist nurse. The wound was photographed weekly.

Over the next 3 weeks, the wound reduced in size, with an increase in granulation tissue formation and other signs associated with a progression towards healing, although some hypergranulation was present (Figs 43–45). The patient reported an improvement after the first two dressing changes, stating that her quality of life had improved and she was regaining her independence. Her self-reported pain VAS score reduced to zero by the third

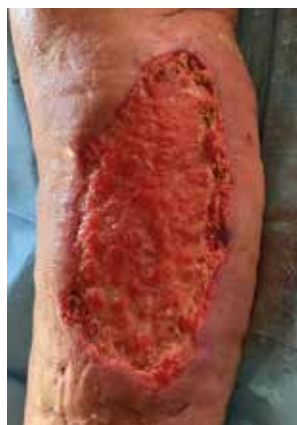

Fig 42. Case study 11: the wound on day 0, before the initiation of treatment with the Wound Hygiene protocol. It measured 15.5 x 8 x 0.4 cm. The wound bed had the characteristics of a non-healing wound including islands of fibrin and hypergranulation tissue

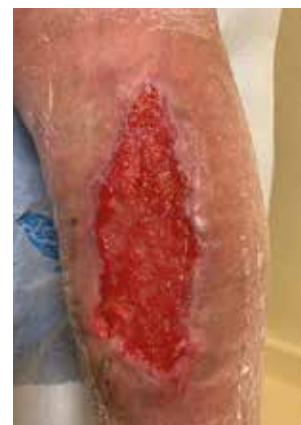

Fig 43. Case study 11: the wound on day 7 of treatment with the Wound Hygiene protocol. It measured 13 x 6 x 0.3 cm and hypergranulation tissue was still present

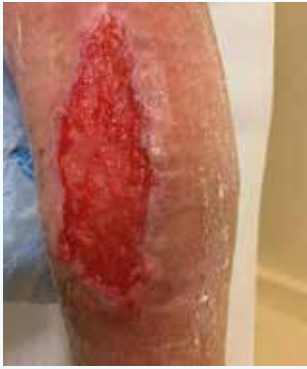

Fig 44. Case study 11: the wound on day 14. It measured 11 x 5.5 cm and some hypergranulation tissue was still present

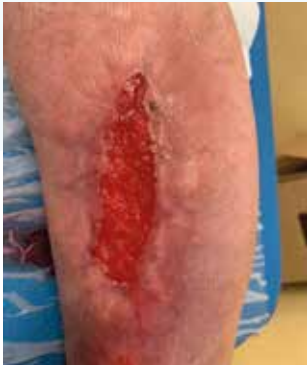

Fig 45. Case study 11: the wound on day 21. The wound size has reduced to 8 x 3 cm

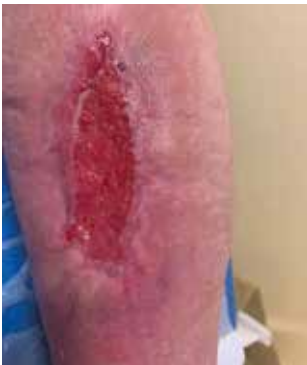

Fig 46. Case study 11: the wound on day 30: it measured 7 x 2 cm

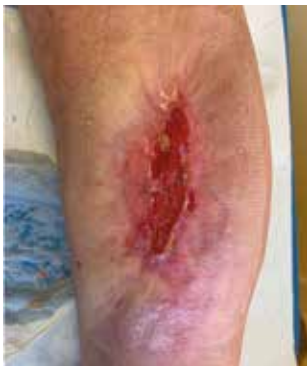

Fig 47. Case study 11: the wound continued to be treated with the Wound Hygiene protocol after the 30-day study period ended. There was an ongoing reduction in wound size

dressing change. On day 21, the dressing regimen was stepped down to Aquacel (primary dressing), along with the polyurethane foam, which was maintained until the wound healed on day 51. Figs 46 and 47 show the wound as it progressed during this time period.

The patient was happy with the treatment provided, as she was able to tolerate it and was pleased with the reduction in wound pain. The home care nurses were also positive about the Wound Hygiene protocol, as it is a simple, four-step process that enables full wound bed preparation, although they did not always implement it systematically. Following this case study, the home care team is now considering incorporating the Wound Hygiene concept into its care pathway.

Case study 11: clinical summary	
Clinical challenges at presentation	Well-vascularised, moderately exuding excision with partly viable wound bed
Wound Hygiene protocol implemented	
Step 1: cleanse	PHMB cleanser
Step 2: debride	Hydrogel and debridement pad*
Step 3: refashion	Curette
Step 4: dress	Aquacel Ag+ Extra dressing and polyurethane foam (weeks 1–3) Aquacel and polyurethane foam (weeks 3–7)
Outcome	Hypergranulation disappeared at week 3, with full healing achieved at week 7
* Curette was used to remove slough	

Case study 12: traumatic wound

Sara Sandroni Nurse Manager and **Elisa Marinelli** Nurse Specialist, both at Network Wound Care, Azienda USL, Toscana Sud Est, Arezzo, Italy

A self-employed farm worker, who is in his 70s, incurred a traumatic injury to the posterior region of his right ankle, above the Achilles tendon, in an accident involving a hoe. As this happened during the COVID-19 pandemic, the patient decided to self-treat the wound and continued with his agricultural work. However, after wearing 'safety work shoes' needed for this employment, the wound deteriorated. His family depended on his work income, so he was unable to reduce his hours. The patient was a cigarette smoker and his only significant morbidity was hypertension, which was well controlled.

The wound was reducing the patient's quality of life significantly: it was painful, and he had to take pain relief in order to perform his activities of daily living. His dressings did not stay inside his shoe, causing him discomfort.

Two months after the injury, the patient attended a hospital emergency room, as the wound pain was increasing. He was sent to the surgical clinic, where he was assessed and the wound cleansed with povidone-iodine-soaked gauze. He was referred to a specialist nurse clinic, which was part of a local nursing and medical network.

Fig 48 shows the wound at presentation at the specialist nurse clinic. There was devitalised tissue on the wound bed, and the wound edges were defined (cliffs), although it was not possible to assess either fully due to other wound-surface residue and debris present. The periwound skin was fragile, dehydrated and slightly oedematous. The wound bed was dry and hard.

Implementation of Wound Hygiene

The specialist nurse explained to both the patient and his GP the importance of a phased sequential protocol in promoting healing. She then implemented the Wound Hygiene protocol.

In step 1, the wound was cleansed with 0.9% sodium chloride solution.

In step 2, it was debrided with a debridement pad (Debrisoft, L&R), which was chosen because it can be performed in the home and was well tolerated by the patient; analgesia (paracetamol) was only required for debridement at the first two dressing changes.

In step 3, the wound edges were stimulated with a curette (without reaching pin-point bleeding) until they became clean and healthy. This was well tolerated by the patient.

In step 4, a hydrogel dressing (Nu-Gel, Systagenix) was applied, which was covered with paraffin-impregnated gauze and a pressure-relieving polyurethane foam (Mepilex XT, Mölnlycke Health Care). The aim was to promote a moist environment that would help promote debridement and granulation tissue formation, while also protecting the wound from pressure and shear when the patient was lying down.

The Wound Hygiene protocol was performed every 5 days (at dressing change) by either the home care nurses or the specialist nurse. The wound was photographed weekly.

Following implementation of the protocol, the wound decreased slightly in size and there was a reduction in fibrin but, due to an increase in wound bioburden and biofilm formation, some areas of hypergranulation appeared and the wound began producing a moderate volume of malodorous exudate. Figs 49 and 50 show the wound at days 7 and 14, respectively. Therefore, from day 14, the Wound Hygiene protocol was changed, as described below.

In step 1, the wound was cleansed for 15 minutes with a PHMB pack (Prontosan Solution, B Braun)

In step 2, it was debrided with a debridement pad. The hydrogel dressing continued to be used to promote debridement.

In step 3, a curette was used as described above.

In step 4, a primary antimicrobial dressing (Aquacel Ag+ Extra dressing) was applied to manage the exudate and reduce the raised bioburden and biofilm. A polyurethane foam dressing to protect the wound from pressure and shear was applied as a secondary dressing.

The wound continued to reduce in size, although the anatomical area that had been subject to friction from the shoe was slow to heal (Fig 51). There was still a moderate volume of malodorous exudate at week 3, and the antimicrobial dressing was continued for the rest of the 30-day follow-up period as it was considered to be aiding wound contraction and improving the overall condition

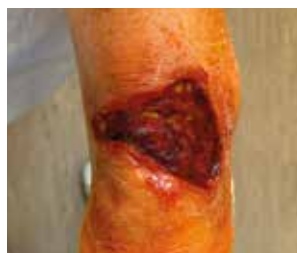

Fig 48. Case study 12: the wound on day 0, before the initiation of treatment with the Wound Hygiene protocol. It measured 7 x 4 x 0.3 cm

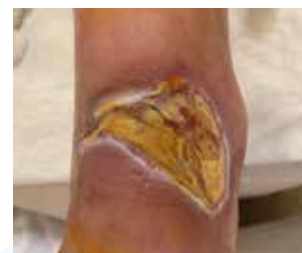

Fig 49. Case study 12: the wound on day 7. It measured 8 x 5 x 0.3 cm

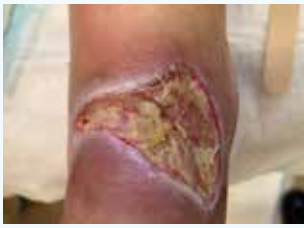

Fig 50. Case study 12:
the wound on day 14. It
measured 8 x 4.5 x 0.3 cm

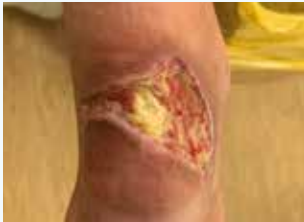

Fig 51. Case study 12:
the wound on day 21. It
measured 7 x 4 x 0.3 cm

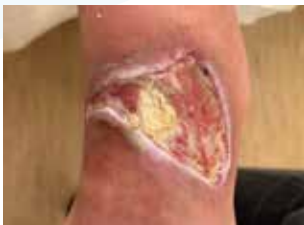

Fig 52. Case study 12:
the wound on day 30. It
measured 6 x 3 x 0.3 cm

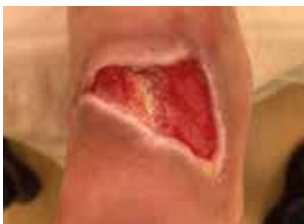

Fig 53. Case study 12:
the wound on day 45. It
measured 5 x 3 x 0.2 cm

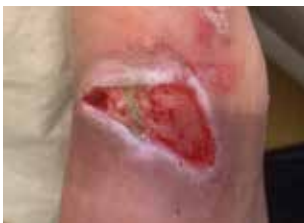

Fig 54. Case study 12:
the wound on day 53. It
measured 4 x 2.5 x 0.2 cm

of the wound bed and reducing the biofilm. In addition, the patient's quality of life improved, with a reduction in previously experienced pressure-related pain.

By day 30, the wound was smaller; although there was no change in the exudate characteristics, it was thought that the biofilm was no longer delaying healing (Fig 52). For step 4, the dressing regimen was stepped down to a hydrogel (Nu-Gel, Systagenix) and Aquacel to maintain a moist environment, manage the exudate and thus protect the wound margins. A silicone barrier spray was used to protect the wound margins.

The patient was very pleased with the care provided, as the pain had reduced and he was able to tolerate the

treatment. He also reported that he had regained his independence.

As the wound was considered to be progressing well, the home care nurses decided to continue using the Wound Hygiene protocol on this patient, under the supervision of the patient's GP. They applied the protocol as described for day 30, with the exception that, for step 2, selective debridement (monofilament pad, Debrisoft, L&R) was used on both the wound bed and margins, and the Hydrofiber and hydrogel dressing was alternated with collagenase/hyaluronic acid (Bionect Start, Fidia) to promote greater hydration. The dressings were now being changed twice weekly.

On day 45, the wound had decreased in size and the patient was no longer experiencing any wound-related pain and stopped taking his pain relief. He was able to resume all his activities of daily living (Fig 53). Fig 54 shows the wound on day 53, when this progression was maintained. The care team is now considering incorporating the Wound Hygiene concept into its care pathway.

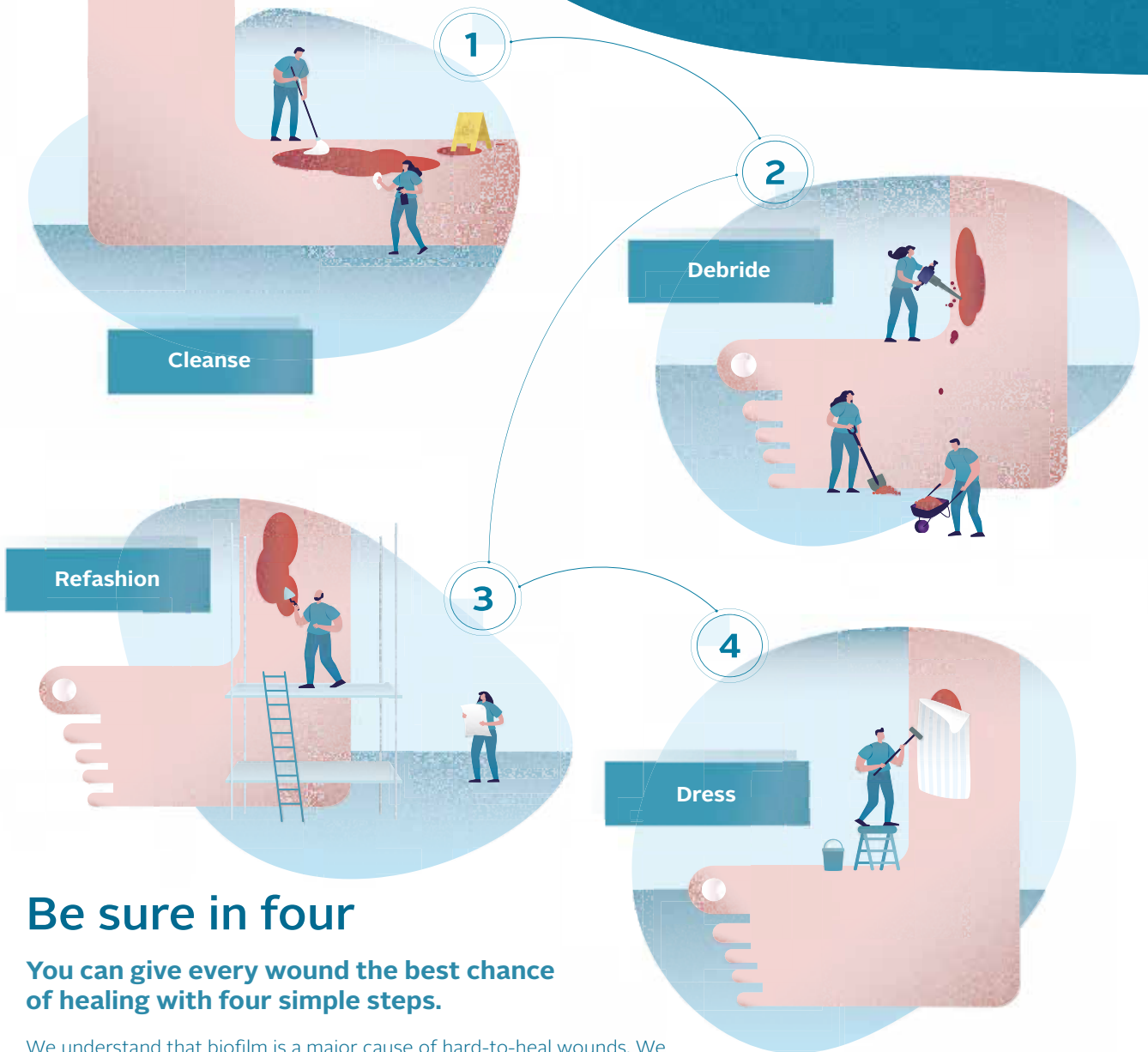
Case study 12: clinical summary

Clinical challenges at presentation	Dry wound with devitalised tissue, defined edges and fragile periwound skin
Wound Hygiene protocol implemented	
Step 1: cleanse	Sodium chloride (weeks 1–2) PHMB cleanser (weeks 3–7)
Step 2: debride	Debridement pad (weeks 1–7) Hydrogel (weeks 3–7)
Step 3: refashion	Curette (weeks 1–4) Debridement pad (weeks 4–7)
Step 4: dress	Hydrogel, paraffin-impregnated gauze and a pressure-relieving polyurethane foam dressing (weeks 1–2) Aquacel Ag+ Extra dressing and a polyurethane foam dressing (weeks 2–4) Hydrogel and Aquacel or a collagenase/hyaluronic acid dressing (weeks 4–7)
Outcome	Initially, some hypergranulation developed, along with moderate volume of malodorous exudate. Following use of an antimicrobial Hydrofiber dressing, the wound began to reduce in size and the exudate level to decrease, resulting in a progression towards healing



Introducing Wound Hygiene™

An early anti-biofilm intervention strategy



Be sure in four

You can give every wound the best chance of healing with four simple steps.

We understand that biofilm is a major cause of hard-to-heal wounds. We believe every wound, no matter how challenging, can progress to healing.

Just as we follow basic hygiene every day by washing our hands, brushing our teeth and showering, we should apply basic hygiene to wounds to keep them clean and remove biofilm.

By implementing Wound Hygiene™, you can ensure every wound is properly prepared for healing every time.

Not everything needs to be complicated. Keep biofilm based wound care simple.

Now published as an International Consensus Document

Download at: www.magonlinelibrary.com/page/jowc/resources



Find out more at www.woundhygiene.com

