

## Introduction

Biofilm is a primary cause of wound chronicity (Høiby et al, 2015; Wolcott et al, 2016; Wolcott, 2017), and is characterised by recurrent inflammation and poor response to antimicrobial therapies (Høiby et al, 2015; Wolcott et al, 2016; Wolcott, 2017).

The results of a systematic review and meta-analysis (Malone et al, 2017) confirm biofilm to be present in around 78% of all chronic wounds. Despite this, a more realistic biofilm prevalence is suspected to be closer to 100% (WUWHS, 2016) in hard-to-heal wounds and therefore supporting clinical assumptions that biofilms are ubiquitous in these types of wounds.

Better understanding and management of biofilm in hard-to-heal wounds – as well as utilising new treatments and technologies – are necessary to improve wound healing outcomes (Wolcott, 2017). A focus on early intervention is also required, in order to manage biofilm before wound chronicity becomes a serious challenge.

## Biofilm and hard-to-heal wounds

Although there is some debate around the exact mechanisms by which biofilm impairs wound healing processes, current data suggest that the wound is kept in a low-grade, ineffective inflammatory state, preventing normal wound healing from occurring (Bjarnsholt et al, 2008; Gurjala et al, 2011). The sustained inflammatory response is associated with elevated levels of proinflammatory cytokines. This leads to an increased number of neutrophils, macrophages and mast cells, which start to secrete proteases and reactive oxygen species (ROS), ultimately destroying host cell activity that is essential for healing. Work from Gurjala and colleagues (Gurjala et al, 2011) also shows that biofilm impairs epithelialisation and granulation tissue formation (*in vivo*). Overall these mechanisms result in the progression to a chronic state with the typical signs and characteristics of hard-to-heal wounds (Bjarnsholt et al, 2008).

The impact of hard-to-heal wounds on patients, practitioners and healthcare systems has been well documented (Guest et al, 2015;

Sen, 2019), with elevated costs, as well as the effects upon patient health and quality of life.

The link between hard-to-heal wounds and biofilm, as well as its consequences, indicates that there is a need for a change in approach, focusing on early intervention through biofilm-based wound care strategies that include: effective wound cleansing, debridement and the use of proven and effective anti-biofilm antimicrobials (Figure 1).

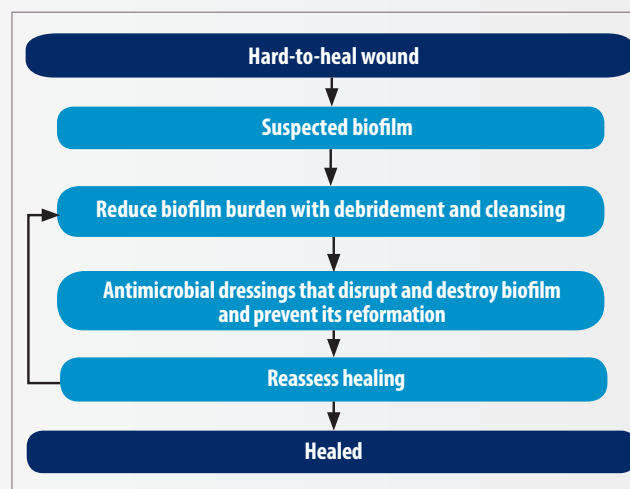


Figure 1. Biofilm-based wound care model (adapted from WUWHS, 2016)

### Box 1: What is a hard-to-heal wound? (Adapted from Frykberg & Banks, 2015; Atkin et al, 2019)

- A hard-to-heal wound can be defined as a wound that fails to proceed through the normal phases of wound healing in an orderly and timely manner and following standard therapies (Troxler et al, 2006).
- Hard to heal wounds are often associated with:
  - Inflammation: stalled state in the inflammation phase of healing.
  - Infection: the wound can appear infected or showing no clear signs of infection.
  - Biofilm: recognised as an important contributor to the hard-to-heal status.
  - Presence of certain risk factors, regardless of time: patient comorbidities, history of wound recurrence, wound complications, etc.
  - Hard-to-heal wounds share certain common features, including excessive levels of proinflammatory cytokines, proteases, ROS, and senescent cells, and a deficiency of stem cells that are often also dysfunctional.

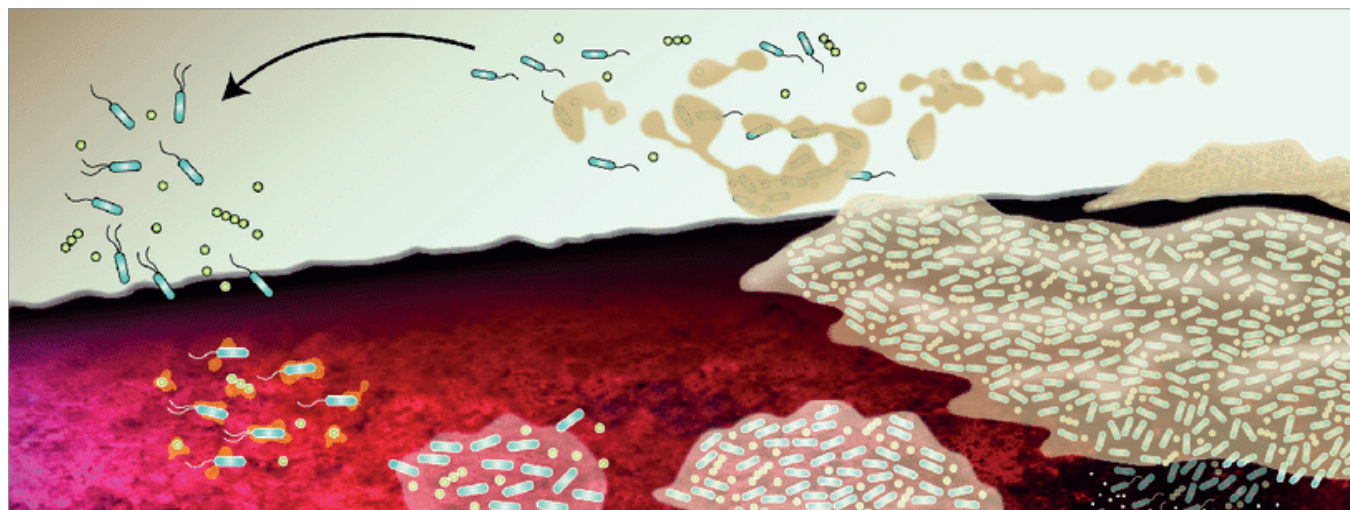


Figure 2. Development and maturation of biofilm in a wound

## The importance of antimicrobials

Biofilm is difficult to eradicate and requires a proactive management approach (WUWHS, 2016). Biofilm formation can begin within minutes of attachment of microbial cells to surfaces within the wound, with progression to a mature state over hours or days depending on the microbial composition (Bester et al, 2010). As biofilm formation progresses, it becomes increasingly tolerant to antibiotics and antiseptics, and is difficult to remove. This means that eradicating biofilm is a time-dependent process, and any biofilm management strategies should take this cycle into account (Figure 2).

Biofilm-based wound care commonly involves physical removal, such as debridement, vigorous cleansing or irrigation. These are key steps in the battle against biofilm and should be the basis of any effective wound management. However, mature biofilm is extremely resilient, so residual biofilm is likely to remain, and has been shown to reform within 24 hours of mechanical disruption (Bester et al, 2010). Therefore, it is important to ensure that residual biofilm, even after debridement and cleansing, is controlled and not given the opportunity to reform by using a sustained-release antimicrobial to effectively prevent biofilm reformation.

Not all topical antimicrobial therapies are the same and not all antimicrobial dressings have been developed specifically to manage biofilm. It is therefore important to opt for technologies that have been designed to combat wound biofilm, utilising a combination of anti-biofilm and antimicrobial agents. Additionally, because of biofilm's self-protecting nature and its modalities of survival, guidelines, such as the European Society for Clinical Microbiology and Infectious Diseases (Høiby, 2015)

are encouraging the use of more advanced technologies that incorporate biofilm-disrupting agents to maximise the effectiveness of the antimicrobial agent against the biofilm's structures.

### Box 2: Desired properties of an anti-biofilm wound dressing

- Ability to disrupt and destroy biofilm structure
- Safe and effective antimicrobial action
- Sustained activity, preventing biofilm reformation
- Exudate management capability: to absorb and retain exudate
- Ability to lock in and sequester bacteria and the disrupted biofilm structures
- Ability to provide a moist wound healing environment to promote autolytic debridement

## Introducing MORE THAN SILVER technology

AQUACEL™ Ag+ Extra™ (ConvaTec Ltd) is a Hydrofiber™ dressing that has been specifically designed to address the challenges of wound exudate, infection and biofilm. MORE THAN SILVER technology is a key component of AQUACEL Ag+ Extra dressings, combining three agents that work synergistically to combat biofilm, and support wound healing (Figure 3).

The absorbent and highly retentive Hydrofiber dressing includes ionic silver, which is well established as an effective antimicrobial agent. In AQUACEL Ag+ Extra dressings, the ionic silver is used in conjunction with other agents that allow the ionic silver to work more effectively against biofilm (Said et al, 2014).

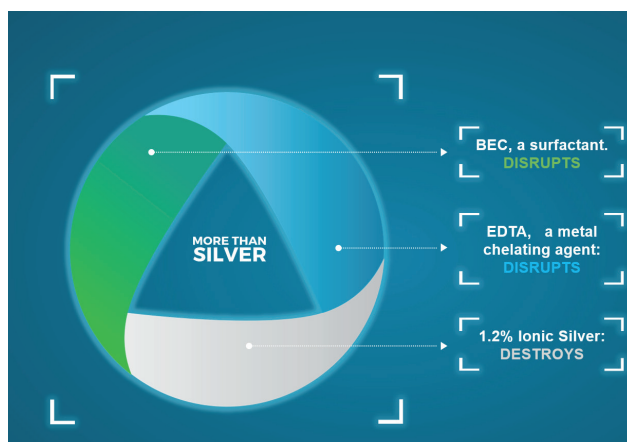


Figure 3. MORE THAN SILVER technology

The three key components are:

1. Benzethonium chloride (BEC), a surfactant. Surfactants help substances to mix and disperse by lowering the surface tension (the cohesive forces) between them. BEC reduces the surface tension between the biofilm and the wound bed, and between components within the biofilm matrix, therefore facilitating its release, dispersal and discouraging its reformation; BEC also facilitates biofilm removal from a wound by enhancing uptake of biofilm debris by the dressing (Said et al, 2014; Seth et al, 2014).
2. Ethylenediaminetetraacetic acid disodium salt (EDTA), a chelating agent. The structure and viscosity of the biofilm matrix is primarily a result of cross-linking with multi-valent metal ions, such as calcium and iron, scavenged by microorganisms from exudate; chelating agents compete for and remove these ions, therefore encouraging the disruption and liquification of the biofilm matrix and preventing its reconstruction (Banin et al, 2006). EDTA also boosts the effect of surfactants, therefore there is a mutual enhancement between the actions of BEC and EDTA (Said et al, 2014).
3. 1.2% ionic silver ( $\text{Ag}^+$ ), an antimicrobial that is active only in its ionised form. Ionic silver is effective at low concentration as it is selectively attracted to sites on bacterial cell walls, accumulating and then entering the cell, where it damages the DNA, denatures proteins and enzymes, and interferes with protein synthesis; the microbial cell wall becomes porous and the contents leak out (Hobot, 2008). This multi-modal microbicidal action of ionic silver results in a broad spectrum of activity and a low propensity

for the development of microbial resistance. The action of BEC and EDTA expose microorganisms previously protected within the biofilm matrix to the antimicrobial effects of the ionic silver (Said et al, 2014).

These three components work synergistically to disrupt and destroy biofilm, and prevent reformation, facilitating wound progression and healing (Said et al, 2014).

## Evidence for MORE THAN SILVER technology

The synergistic (mutually enhancing) ability of these three components to disrupt and destroy biofilm, and prevent its reformation, has been demonstrated *in vitro* (Said et al, 2014). This study showed that EDTA and BEC, neither alone nor in combination, had any bactericidal effect against bacterial biofilm, but when added to ionic silver they facilitated biofilm disruption and enhanced the antimicrobial effect of ionic silver.

An *in vitro* study demonstrated that the combination of ionic silver with a metal chelating agent and a surfactant in a dressing format was found to produce a synergistic effect that substantially improved the antimicrobial efficacy of ionic silver against biofilm (Bowler & Parsons, 2016). The study concluded that use of these combined elements in the dressing has been proven to contribute significantly to managing biofilm infections and encouraging healing in patients living with challenging hard-to-heal wounds (Bowler & Parsons, 2016).

A clinical evaluation using AQUACEL Ag+ Extra dressings in stalled or deteriorating wounds that were considered to be compromised by infection and/or biofilm, assessed the dressing's ability in managing wound exudate, infection and biofilm, and facilitating progression toward healing (Metcalf et al, 2017). After an average management period of 3.9 weeks, wound statuses were shifted from stagnant/deteriorating to mainly improved, and exudate levels were shifted from moderate/high to moderate/low. All signs of clinical infection were reduced in average frequency, with biofilm suspicion falling from 54% to 27% of the cases. It was concluded that the dressing's successful management of exudate, infection and biofilm resulted in notable improvements in wound health and size. See Figure 4 for the wound statuses at baseline and after evaluation in this study.

## Winning the battle to advance healing: AQUACEL™ Ag+ dressings advance healing in stalled, deteriorating chronic wounds

### Study

111 patients, with non-healing wounds from 60 centres across the UK and Ireland.

### Results

- 78% of wounds progressed towards healing, 13% healed completely during an average evaluation period of 3.9 weeks.
- 83% of the wounds progressed in key wound healing parameters (exudate, suspected biofilm and wound healing status).
- Biofilm was suspected more frequently (54%) than any other clinical sign of infection at baseline. This reduced to 27% at the final evaluation.

### Objective

To demonstrate the ability of AQUACEL Ag+ Extra dressings to promote healing in chronic wounds that were stalled or deteriorating at baseline.

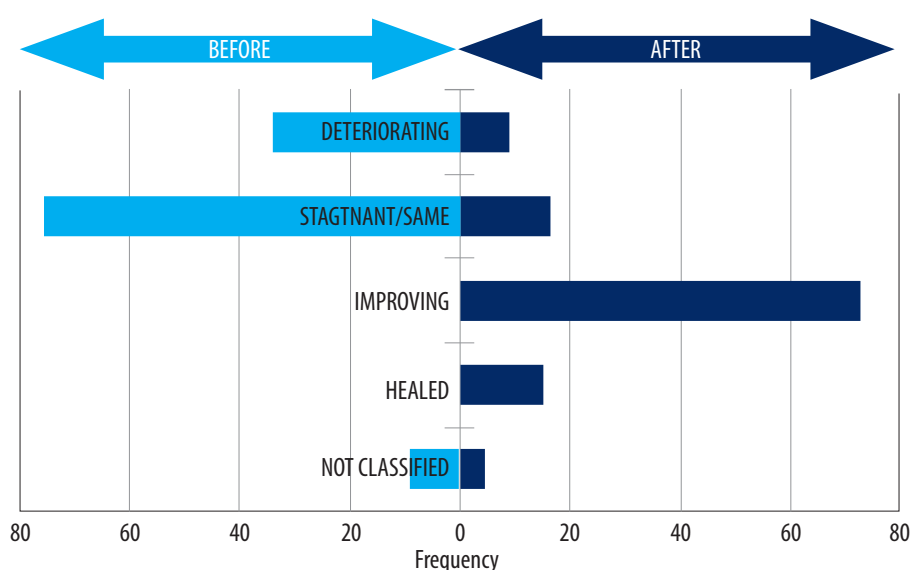


Figure 4. Wound status at baseline (light blue) and after introduction of AQUACEL Ag+ Extra dressings (dark blue), from Metcalf et al (2017)

A study assessing the safety and effectiveness of the dressing in chronic venous leg ulcers exhibiting signs of clinical infection treated patients for 4 weeks with AQUACEL Ag+ dressings (without strengthening fibres), followed by management with AQUACEL dressings for 4 weeks (Harding et al, 2016). After 8 weeks, substantial wound improvements were observed: 12% of patients had healed ulcers and 76% showed improvement in ulcer condition. The mean ulcer size had reduced by 55%. Patients reported less pain as the study progressed. Notable improvements were observed in patients with ulcers that were considered to require treatment with systemic antibiotics or topical antimicrobials at baseline, with a mean 70% reduction in wound area. The dressing was also found to have an acceptable safety profile and tolerability.

An *in vivo* study using a porcine non-contaminated deep partial thickness wound model assessed the effects of AQUACEL Ag+ Extra dressings on normal wound healing (Davis et al, 2018). The study concluded that there was no notable interference in normal wound healing compared

to a silver Hydrofiber dressing (without anti-biofilm technology) and a polyurethane film dressing.

## Case studies

These findings are also reflected in case study 1 and 2 where AQUACEL Ag+ Extra dressings were used as part of a treatment regimen to improve ulcer conditions. In the first case, AQUACEL Ag+ Extra dressings were selected for use to address signs of biofilm. This regimen proved to be effective in resolving infection and progressing the wound to healing. Use of AQUACEL Ag+ Extra dressings in the second case presented a wound that had significantly reduced in size during treatment, with positive progression noted. This case observed reduced levels of exudate and improved mobility. After 28 days of treatment the wound had healed.

### Case study 1 (courtesy of Katia Furtado)

- 68-year-old female, initially admitted to hospital following a fall resulting in a fractured femur
- Several comorbidities, including: hypertension, chronic venous disease, chronic renal disease, rheumatoid arthritis, dyslipidaemia, depression and deep vein thrombosis
- Previously mobile and active, working in a busy job
- Following surgery for the fracture, her renal insufficiency worsened and dialysis was required. She developed a surgical site infection and two further leg ulcers were identified (Figures 5a and b)
- Further surgical management was attempted to close the leg ulcers, but was unsuccessful
- A wound care plan was implemented:
  - All sutures were removed

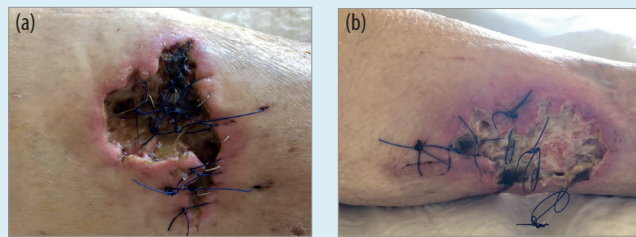


Figure 5. Wounds at presentation, before the use of AQUACEL Ag+ Extra dressings: (a) Left leg (b) right leg

- Wound was cleansed with saline water and debrided with the help of a dermal curette
- AQUACEL Ag+ Extra dressings selected due to signs of biofilm, used as primary dressing and fixed with a gauze bandage from toes to knee
- Dressing changed three times a week
- Previous antibiotics stopped
- Pain managed with transcutaneous morphine, and nutritional issues addressed by adding two hyper-protein and hyper-caloric supplements to the patient's daily diet.

- Regimen using AQUACEL Ag+ Extra dressings managed the infection within 8 weeks, following which a foam dressing was selected and the wound progressed to healing (Figures 6a and b).

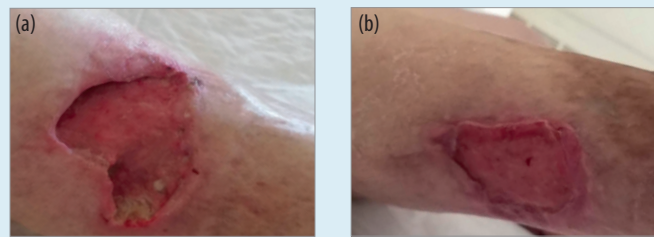


Figure 6. After 8 weeks using AQUACEL Ag+ Extra dressings: (a) Left leg (b) right leg

### Case study 2 (courtesy of Kathryn Braun)

- 47-year-old male, presenting with a diabetic foot ulcer (DFU) of 2 months' duration
- Caused by pressure owing to insufficient offloading of the plantar aspect of the right foot, exacerbated by over-exuberant debridement of callus
- History of type 1 diabetes, treatment with anti-rejection drugs after a kidney transplant in 1999 and underlying comorbidities of congestive heart failure and lymphoedema
- On presentation, the DFU measured 1.8 cm in length, 1.2 cm in width, with 0.6 cm depth (approximately 1.3 cm<sup>3</sup> in volume). There was also localised undermining of approximately 1 cm (Figure 7a)
- Wound symptoms: macerated peri-wound skin and malodorous, purulent exudate, plus high levels of pain and reduced mobility
- Prior wound management included a cadexomer iodine dressing covered with a foam dressing

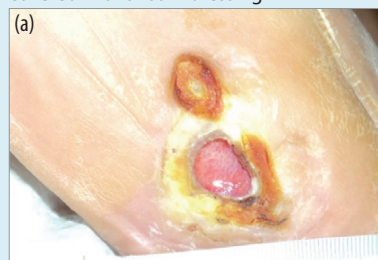

Figure 7a. On presentation

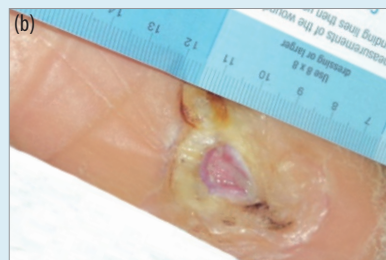

Figure 7b. After 14 days of using AQUACEL Ag+ Extra dressings

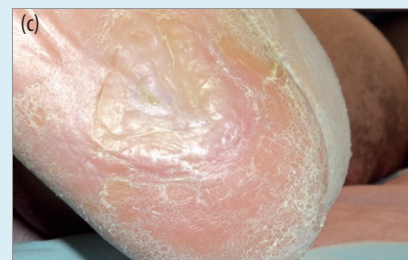

Figure 7c. After 28 days of using AQUACEL Ag+ Extra dressings

- AQUACEL Ag+ Extra dressings were introduced, used as the primary dressing, with continued use of a secondary foam dressing (changed in line with local protocols)
- Following 14 days of treatment with AQUACEL Ag+ Extra dressings, the DFU had significantly reduced in both length and width, with positive progression from 40% yellow sloughy tissue to 100% red granulation tissue (Figure 7b)
- Exudate levels had reduced and were sero-sanguinous rather than sero-purulent. Offloading padding was applied into the patient's footwear to increase comfort, as the wound had nearly closed and mobility improved
- After 28 days of regimen using AQUACEL Ag+ Extra dressings, the DFU had closed completely (Figure 7c).

## Why wait?

Recent evidence has made it apparent that a shift to early and aggressive biofilm intervention is required (Edens et al, 2019). However, in a recent survey, although 81% of respondents regarded infection and inflammation as the most important factor influencing wound healing outcomes, 19% said they would wait beyond 5 weeks before considering a new product or therapeutic approach (Ousey et al, 2018).

It is now acknowledged that this 'watch and wait' approach is not effective, and by the time a wound has been defined as chronic, we may have already waited too long (Webb, 2017). Delayed attention or ineffective treatment nurtures biofilm, causing non-healing wounds to escalate (Edens & Stevenson, 2019). As such, it is evident that novel strategies are needed, such as MORE THAN SILVER technology, involving the use of advanced dressings that provide combined anti-biofilm and antimicrobial activity. AQUACEL Ag+ Extra dressings should be considered as part of a biofilm-based wound care approach in all wounds that fail to heal normally.

MORE THAN SILVER technology in AQUACEL Ag+ Extra dressings combines three key components that work synergistically to combat biofilm and facilitate wound healing. This synergistic action has been proven to be effective in tackling the problem of biofilm, thus facilitating healing and helping to improve outcomes in the management of hard-to-heal wounds.

### Authors:

**Katia Furtado**, Nurse Specialist, ULSNA  
(Unidade Local de Saúde do Norte Alentejano),  
Hospital Outpatient Department, Portugal

**Vincent Siaw-Sakyi**, Tissue Viability Nurse  
Specialist, Kent Community Health NHS  
Foundation Trust, UK

**Philip Bowler**, VP Science & Technology, R&D,  
ConvaTec, UK

This Made Easy supplement was supported by an educational grant from ConvaTec.

AQUACEL, AQUACEL Extra and Hydrofiber are trademarks of ConvaTec Inc. All trademarks are the property of their respective owners. ©2019 ConvaTec Inc. AP-020513-MM

V1545

## References

- Atkin L, Bučko Z, Montero EC et al (2019) Implementing TIMERS: the race against hard-to-heal wounds. *J Wound Care* 23(3): s1-52
- Banin E, Brady KM, Greenberg EP (2006) Chelator-induced dispersal and killing of *Pseudomonas aeruginosa* cells. *Appl Environ Microbiol* 72: 2064-9
- Bester E, Kroukamp O, Wolfaardt GM et al (2010) Metabolic differentiation in biofilms as indicated by carbon dioxide production rates. *Appl Environ Microbiol* 76(4): 1189-97
- Bjarnsholt T, Kirketerp-Møller K, Jensen PO et al (2008) Why chronic wounds will not heal: a novel hypothesis. *Wound Repair Regen* 16(1): 2-10
- Bowler PG, Parsons D (2016) Combatting wound biofilm and recalcitrance with a novel anti-biofilm Hydrofiber wound dressing. *Wound Medicine* 14: 6-11
- Davis SC, Li J, Gil J (2018) The wound-healing effects of a next-generation anti-biofilm silver Hydrofiber wound dressing on deep partial-thickness wounds using a porcine model. *Int Wound J* 1-6. Available online at doi: 10.1111/iwj.12935
- Edens C, Stevenson P (2019) Outliers: Reexamining wounds that fail to heal. *Wound Manag Prev* 65: 8-9
- Frykberg G, Banks J (2015) Challenges in the treatment of chronic wounds. *Adv Wound Care* 4(9): 560-82
- Guest J, Ayoub N, McIlwraith T (2015) Health economic burden that wounds impose on the National Health Service in the UK. *BMJ Open* 5(12)
- Gurjala AN, Geringer MR, Seth AK (2011) Development of a novel, highly quantitative in vivo model for the study of biofilm-impaired cutaneous wound healing. *Wound Repair Regen* 19(3): 400-10
- Harding KG, Szczepkowski M, Jacek Mikosiński et al (2016) Safety and performance evaluation of a next-generation antimicrobial dressing in patients with chronic venous leg ulcers. *Int Wound J* 13(4): 442-8
- Hobot J, Walker M, Newman G et al (2008) Effect of hydrofiber wound dressings on bacterial ultrastructure. *J Electron Microscop* (Tokyo) 57(2): 67-75
- Høiby N, Bjarnsholt T, Moser C et al (2015) ESCMID guideline for the diagnosis and treatment of biofilm infections. *Clin Microbiol Infect* 21 (Suppl 1): s1-25
- Malone M, Bjarnsholt T, McBain AJ et al (2017) The prevalence of biofilms in chronic wounds: a systematic review and meta-analysis of published data. *J Wound Care* 26(1): 20-5
- Metcalf GD, Parsons D, Bowler PG (2017). Clinical safety and effectiveness evaluation of a new antimicrobial wound dressing designed to manage exudate, infection and biofilm. *Int Wound J* 14(1): 203-13
- Ousey K, Gilchrist B, Jaimes H (2018) Understanding clinical practice challenges: a survey performed with wound care clinicians to explore wound assessment frameworks. *Wounds Int* 9(4): 58-62
- Said J, Walker M, Parsons D et al (2014) An in vitro test of the efficacy of an anti-biofilm wound dressing. *Int J Pharm* 474: 177-81
- Sen CK (2019) Human wounds and its burden: An updated compendium of estimates. *Adv Wound Care* 8(2)
- Seth AK, Zhong A, Nguyen KT et al (2014) Impact of a novel, antimicrobial dressing on in vivo, *Pseudomonas aeruginosa* wound: quantitative comparative analysis using a rabbit ear model. *Wound Repair Regen* 22: 712-9
- Troxler M, Vowden K, Vowden P (2006) Integrating adjunctive therapy into practice: the importance of recognising 'hard-to-heal' wounds. *World wide Wounds*. Available online from [www.worldwidewounds.com](http://www.worldwidewounds.com)
- Webb R (2017) A chronic case of confusion. *J Wound Care* 26(8): 421
- Wolcott RD (2017) Biofilms cause chronic infections. *J Wound Care* 26(8): 423-5
- Wolcott R, Sanford N, Gabriliska R et al (2016) Microbiota is a primary cause of pathogenesis of chronic wounds. *J Wound Care* 25(Sup10): S33-43
- World Union of Wound Healing Societies (2016) Florence Congress Position Document: Management of biofilm. Available online from [www.woundsinternational.com](http://www.woundsinternational.com)